

REVIEW ARTICLE

Paradigms, Paradoxes, and Controversies on Keratoconus and Corneal Ectatic Diseases

¹Renato Ambrósio Jr, ²Fernando Faria-Correia, ³Ícaro Silva-Lopes, ⁴Allan Azevedo-Wagner, ⁵Faride W Tanos
⁶Bernardo Lopes, ⁷Marcella Salomão

ABSTRACT

In this review/opinion article, we prospectively discuss the evolution of knowledge related to keratoconus and ectatic corneal diseases (ECDs), which is intimately related to the emergence of modern refractive surgery in the early 1980s. This is linked, but goes further beyond the need for screening candidates at risk for progressive keratectasia prior to refractive laser vision correction (LVC). In this scenario, we evolved from early diagnosis of keratoconus toward the characterization of the individual susceptibility for ectasia development. There was a paradigm shift related to the management of ECDs, which was unsophisticated and limited to spectacles, rigid contacts lens, or penetrating keratoplasty (PKP). In fact, the emergence of novel treatment modalities, such as corneal cross-linking (CXL) and intrastromal corneal ring segments (ICRS), has established conflicting situations on when, why, and how to proceed with surgery on these patients. Such paradoxes determine the need for individualized treatment planning, which should consider accurate evaluation of patient needs, advanced imaging with advanced geometric characterization, biomechanical assessment, and environmental factors. In addition, patient (and family) education has become an essential part of the management in order to allow conscious decisions and set realistic expectations. In addition, explaining patients that eye rubbing is a major factor on ectasia progression has gained its momentum with the JUNE VIOLET campaign. Such enhanced understanding has led "corneal ectasia" to be considered as a novel subspecialty in ophthalmology.

Keywords: Corneal cross-linking, Corneal imaging, Ectatic corneal diseases, Eye rubbing, Intrastromal corneal ring segments, Keratoconus, Patient education.

How to cite this article: Ambrósio R Jr, Faria-Correia F, Silva-Lopes Í, Azevedo-Wagner A, Tanos FW, Lopes B, Salomão M. Paradigms, Paradoxes, and Controversies on Keratoconus and Corneal Ectatic Diseases. *Int J Kerat Ect Cor Dis* 2018;7(1):35-49.

Source of support: Nil

Conflict of interest: None

INTRODUCTION

In 1854, John Nottingham provided the primary truthful report of keratoconus covering many aspects that are still relevant nowadays, which was coined as "conical cornea" (Fig. 1). Despite the general limitations related to the knowledge on basic sciences including anatomy, biochemistry, and physiology, Nottingham's landmark publication described in detail several features of ECDs that are still relatively accurate and relevant today.¹ Previously, other authors already had performed less consistent reports of the disease. Interestingly, ECDs were erratically designated by different concepts, such as "hyperkeratosis," "conical formed cornea," "sugar loaf cornea," "prolapses corneae," "procidentia corneae," "staphyloma pellucidum," or "staphyloma diaphanum."²

REFRACTIVE SURGERY AS A "GAME CHANGER"

In the early 1980s, the advent of elective procedures performed on normal corneas aiming to reduce refractive error boosted the need for knowledge related to kerato-

¹Founder, Scientific Director, Adjunct Professor, and Affiliated Professor, ²Research Associate and Associated Professor
³⁻⁵Research Associate, ^{6,7}Research Associate and PhD Doctorate

¹Rio de Janeiro Corneal Tomography and Biomechanics Study Group, Rio de Janeiro, Brazil; Department of Ophthalmology Federal University of the State of Rio de Janeiro, Rio de Janeiro Brazil; Department of Ophthalmology, Federal University of São Paulo, São Paulo, Brazil

²Rio de Janeiro Corneal Tomography and Biomechanics Study Group, Rio de Janeiro, Brazil; Department of Ophthalmology School of Health Sciences, University of Minho, Braga, Portugal

³⁻⁵Rio de Janeiro Corneal Tomography and Biomechanics Study Group, Rio de Janeiro, Brazil

^{6,7}Rio de Janeiro Corneal Tomography and Biomechanics Study Group, Rio de Janeiro, Brazil; Department of Ophthalmology Federal University of São Paulo, São Paulo, Brazil

Corresponding Author: Renato Ambrósio Jr, Rua Conde de Bonfim 211/712, Rio de Janeiro-20520-050, Brazil, Phone: +552122344233, e-mail: dr.renatoambrosio@gmail.com

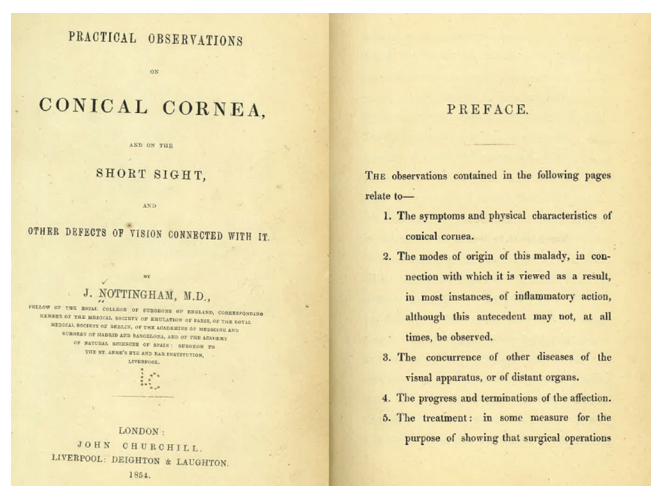


Fig. 1: The seminal treatise by J Nottingham on conical cornea (1854)



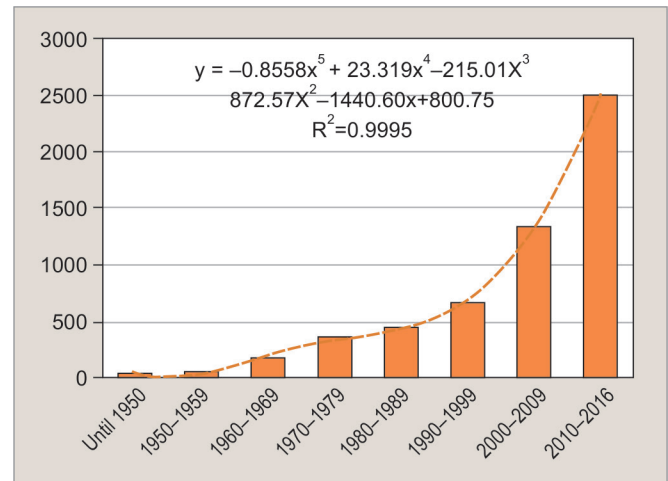
Fig. 2: The Rio de Janeiro Corneal Tomography and Biomechanics Study Group

conus and ECDs. Thereby, the emergence of “refractive surgery” as a subspecialty stimulated an unremitting, continuous, and accelerated evolution in the understanding and management of such diseases.³⁻⁶ In addition, “corneal ectasia” may be also considered as a new subspecialty in ophthalmology, due to high incidence of the disease,⁷ and to the development of novel equipment and knowhow for the diagnosis and treatment.³ This was the scope of the film produced by The Rio de Janeiro Corneal Tomography and Biomechanics Study Group (Fig. 2) in 2012 entitled “Advances in Diagnosis and Treatment of Keratoconus: Are We Facing a New Subspecialty?” (<https://www.youtube.com/watch?v=mVQE7n0u3ZI>), and was intimately related to the development of the International Journal of Keratoconus and Ectatic Corneal Diseases in 2013 (<http://www.ijkecd.com>).

A PubMed review on the published papers found 5,588 publications in December 2016, which increased to 6,301 in July 2018 (PubMed search for “keratoconus”). While there was an increase of over 10% in the last 12 months, the total number of publications over the last year surpasses all articles published up to 1980 and this is also more than the entire decade of 1990. Graph 1 presents the number of new articles published per decade, in which one can conclude that after modern “refractive surgery” was introduced, a significant augment on the scientific publications was initiated. Considering these data, this is likely that we will exceed 10,000 publications by the end of the current decade.⁶ This clearly reflects the increase in relevance of the disease and the progress that definitively enhances our aptitude to assist and help the patients.

THE QUEST FOR EARLY DIAGNOSIS

The advent of elective “Refractive Surgery” called for the sensitivity for earlier diagnosis of mild or subclinical forms of ECDs, because such cases are known to be at



Graph 1: Number of publications on “keratoconus” on PubMed per period

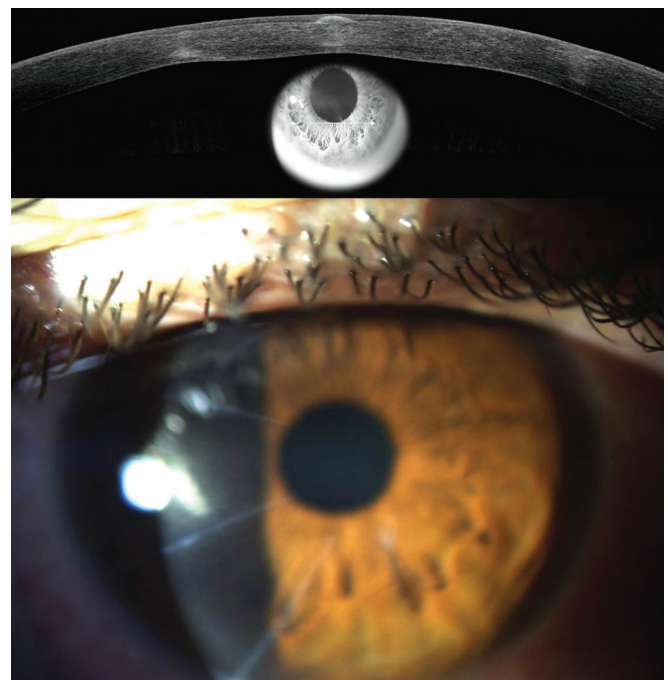


Fig. 3: Ectasia after radial keratotomy. FD-OCT (RTVue, Optovue; Fremont, CA) with the “sausage” sign, indicating corneal thinning at the incisions and slit-lamp frontal view

very high risk for biomechanical decompensation and progressive keratectasia after such procedures, including incisional surgery (Figs 3 to 5),⁸ and refractive corneal or LVC procedures.^{9,10} The terms subclinical, suspect, and fruste have been fitfully used for referring to such cases. Interestingly, the actual definitions for each of these terms are not clear, as there is no consensus on what these terms mean.⁴ Therefore, we prefer to refer to those cases as with high susceptibility for developing ectasia,¹¹ which should be characterized based on objective data from advanced corneal diagnostic technologies.

The last three decades witnessed a factual and continuous revolution in corneal imaging, which includes the

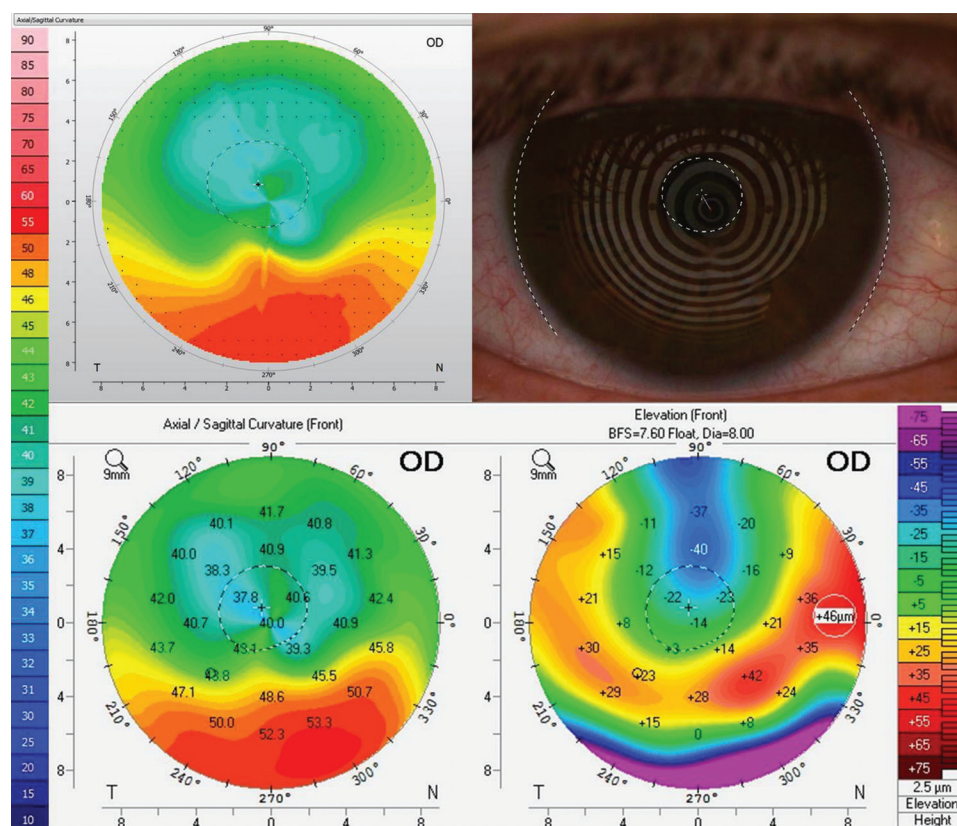


Fig. 4: Axial (sagittal) front surface curvature maps from Placido (Keratograph 5M; Oculus) and Scheimpflug and front elevation from Pentacam HR

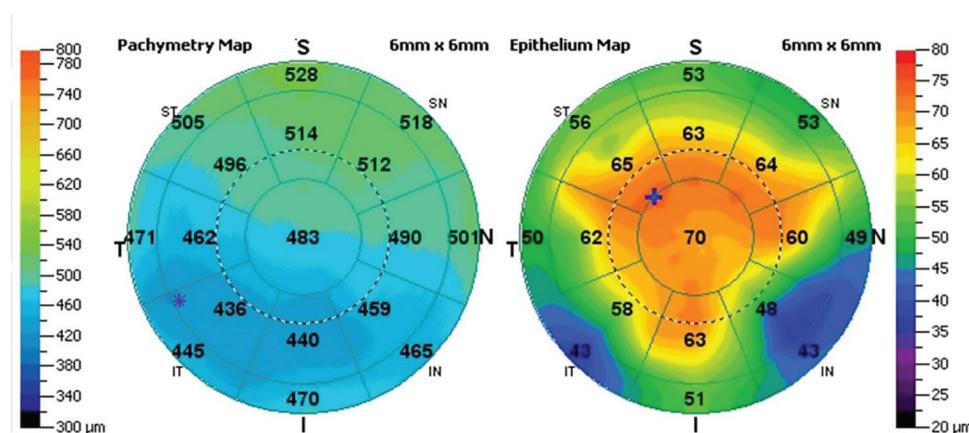


Fig. 5: Segmental tomography from FD-OCT (RTVue) with total pachymetric and epithelial thickness maps limited to 6 mm zone

development of high-resolution technologies capable of detailed characterizations of different aspects of corneal shape and anatomy. In addition, scientifically validated methods for clinical interpretations of the vast amount of data generated were introduced to enable and help improve the clinical decision process.¹² Placido disk-based corneal topography characterizes the anterior or front corneal surface in detail, which enables the detection of abnormal patterns of corneal shape that accompany mild forms of keratoconus in cases in which the routine clinical tests are within normal findings.^{13,14} Such augmentation

of sensitivity to detect ectasia in such eyes with normal slit-lamp biomicroscopy and normal distance-corrected visual acuity (DCVA) has positioned corneal topography as an obligatory exam for screening candidates prior to LVC.^{9,10,13,14} Nonetheless, there are still cases that undergo keratectasia after LVC procedures, even for low-to-mild corrections, notwithstanding relatively normal topography findings prior to laser-assisted *in situ* keratomileusis (LASIK),¹⁵⁻¹⁷ surface ablation,¹⁸ or small-incision lenticule extraction.¹⁹ Contrarily, there are cases with preoperative irregular corneal topography that would have

been considered at high risk and therefore disqualified from having surgery based on the topometric (anterior surface curvature) characteristics, but had proceeded with LASIK considering data from advanced corneal imaging, and had uneventful stable outcomes.²⁰ Those clinical scenarios provide absolute confirmation for the need for enhancing the accuracy augmented with either sensitivity or specificity for ectasia risk assessment.^{10,21}

Developments in corneal diagnostic technologies include corneal tomography and biomechanical assessments.^{12,22} Front surface corneal analysis (topometric or topography) evolved into the three-dimensional (3D) tomographic characterization, which represents elevation of the back and front surfaces along with thickness mapping.²³ Eyes with normal topometric results from patients with clinical ectasia in the fellow eye have been commonly studied to demonstrate the improved ability of corneal tomography to detect ECDs.^{11,24-26} In addition, the ability of tomographic data was studied to augment the aptitude to identify ectasia risk or susceptibility in retrospective analysis of cases that underwent keratectasia after LASIK.^{11,16,22}

The challenge for most clinicians is the interpretation for proper clinical decision based on the enormous amount of clinical data generated by these exams. Considering such encounter, the Pentacam Belin/Ambrósio Enhanced Ectasia Display (BAD) was designed to be a comprehensive tool for displaying tomographic data. The BAD considers the standard and enhanced benign fasciculation syndrome (BFS) elevation maps of the front and back surfaces, along with tomographic thickness profile data. Different tomographic parameters are displayed as the deviations from the norm values toward disease (d values), including anterior and posterior elevation at the thinnest point (considering the 8 mm BFS with float), change in anterior and posterior elevation of the standard and enhanced BFS, thinnest value and its vertical location, pachymetric progression increase, Ambrósio's relational thickness, and maximal curvature (KMax). The final BAD-D, currently in its third version, is a final parameter that was calculated using linear regression analysis (LRA) to maximize the ability for detecting ectatic disease.^{22,25,27,28} The BAD-D higher than 2.11 was a criterion with sensitivity and specificity of 99.59 and 100% for diagnosing keratoconus, while for detecting mild or subclinical disease, the criterion of higher than 1.22 provided 93.62% sensitivity and 94.56% specificity.²⁵ Interestingly, in a retrospective nonrandomized study involving preoperative LASIK data from an international pool comprising of 23 post-LASIK ectasia cases and from 266 stable LASIK with over 1-year follow-up, the criterion of BAD-D higher than 1.29 provided 87% of sensitivity and 92.1% of specificity.²⁹ Even though the BAD-D was the most accurate parameter in predicting ectasia risk,

the data suggest the unquestionable need for further improvements.¹¹

Further developments on corneal diagnostic imaging technologies allowed for segmental or layered tomographic (3D) characterization with epithelial,³⁰⁻³² and Bowman's layer regularity characterization and thickness mapping.³³ While corneal epithelial thickness was initially presented by the digital very-high-frequency ultrasound,³⁴ advances in corneal and anterior segment optical coherence tomography (OCT) allowed for such evaluation. The advent of OCT epithelial thickness mapping^{30,35} may significantly impact either the safety or the efficacy of refractive surgery, being also very important for improving therapeutic procedures.³⁶

Beyond shape analysis, clinical biomechanical assessment has been promised as an ultimate tool (before genetic analysis is available) for enhancing the overall accuracy for identifying mild forms of ECDs, along with the representation of the natural susceptibility of the cornea for ectasia progression.^{16,22} In fact, this is an agreement that the pathophysiology of corneal ectasia is related to abnormal biomechanical properties.⁴ The present perception proposed by Roberts and Dupps³⁷ is that a focal abnormality or weakness in corneal biomechanical properties precipitates a cycle of pathology, leading to secondary localized thinning and steepening (bulging), which generates optical aberrations.³⁷

The Reichert ocular response analyzer (ORA) is a noncontact tonometer (NCT) that was introduced as the pioneer instrument for clinical *in vivo* biomechanical assessment.³⁸ The ORA has a collimated air pulse the peak of which is adjusted according to the measured intraocular pressure (IOP). Corneal deformation is monitored by the apical reflex of an infrared light that goes through a pinhole system toward the sensor. While the first generation of ORA pressure-dependent parameters, corneal hysteresis and corneal resistance factor, provided relatively low sensitivity and specificity for discriminating keratoconic from normal corneas,³⁹ the parameters derived from the waveform signal that characterize corneal deformation during the NCT exam were found to have higher accuracy.⁴⁰ Interestingly, such data were found useful to improve diagnostic accuracy for mild forms of ECDs when combined with tomography data.^{22,41}

The Corvis ST (OCULUS Optikgeräte GmbH; Wetzlar, Germany) is also an NCT, but utilizes an ultra high-speed Scheimpflug camera to monitor the deformation of the cornea in greater detail. It also has a collimated air pulse, but has a fixed pressure profile.⁴² Interestingly, the first set of parameters derived from the Corvis ST measurement also had a relatively poor discriminant ability to detect ectatic diseases.⁴³⁻⁴⁵ Nevertheless, novel parameters, such as the inverse concave radius of curvature

during the concave phase of the deformation response, the deformation amplitude ratio between the apex and at 2 mm from the apex (DA ratio 2 mm), and the stiffness parameter at first applanation were found to improve detection of ECDs.⁴⁶⁻⁴⁸ Vinciguerra et al⁴⁸ developed the Corvis biomechanical index (CBI) using LRA for combining parameters from the deformation corneal response and from the horizontal thickness profile.⁴⁹ The CBI has high accuracy to detect clinical keratoconus.⁴⁸ Besides detection of ECDs, the characterization of the deformation response has also provided an equation for IOP correction. The biomechanically corrected IOP reduces reliance of IOP measurements on both corneal thickness and age,^{50,51} being demonstrated to have lower variation after corneal surgery.⁵²

INTEGRATED SCHEIMPFLUG IMAGING FOR ENHANCED ECTASIA DETECTION

While the ideal cases for representing the eyes with high risk for ectasia progression are the preoperative cases that underwent keratectasia after LVC procedures,^{10,29,53} the fellow eyes with normal topography from patients with clinical ectasia in the other eye have been commonly studied for developing and testing diagnostic tools that have higher accuracy than corneal topography.^{24-26,41,54-58} In that way, those very asymmetric ectasia (VAE) cases have been included in the analysis for the development and further validations of models for enhanced ectasia detection that integrate geometrical and biomechanical data.

Ambrósio et al⁵⁹ described the tomographic/biomechanical index (TBI) that combines Scheimpflug-based corneal tomography and biomechanics using innovative artificial intelligence (AI) techniques for optimizing ectasia detection. As the CBI study,⁴⁸ this was a multicenter study in conjunction with Dr Vinciguerra, combining populations from Rio de Janeiro and Milan. However, the “TBI Study” had an expanded population including 94 VAE cases, which constitutes one of the largest cohort studies with such special group of cases.^{24-26,54} Data from the Pentacam and Corvis ST were combined using different AI methods. The random forest method with leave-one-out cross-validation gave the best model with higher accuracy. The TBI had 100% sensitivity and specificity for distinguishing normals ($n = 480$) and clinical ectasia eyes ($n = 276$) with 0.79 as cut-off. Seventy-two non-operated eyes with clinical ectasia were included as ectatic eyes from very asymmetric ectasia cases (VAE-E), so that the TBI had similar accuracy to that in the keratoconus group. Considering the fellow eyes with normal topography (VAE-NT group), the optimized cut-off value of 0.29 had 90.4% sensitivity ($n = 94$), with 96% specificity.⁵⁹ Very

importantly, the “TBI Study” had a restriction criteria for clinical diagnosis of ectasia, which included topographic characteristics, such as skewed asymmetric bow-tie, inferior steepening, and at least one slit-lamp finding (Munson’s sign, Vogt’s striae, Fleischer’s ring, apical thinning, and Rizutti’s sign).⁶⁰ Patients were considered as very asymmetric if the diagnosis of ectasia was unquestionable in one eye and the fellow had normal objective topometric values, including KISA% lower than 60 and a paracentral inferior–superior asymmetry value at 6 mm (3 mm radii) less than 1.45.⁶¹ These objective criteria are fundamental in order to avoid problems related to the subjectivity and inter- and intraexaminer variability of the classifications of topographic maps.⁶² In this cohort, the BAD-D^{16,22,25,27,48,63-65} had 98.2% sensitivity to detect clinical ectasia (keratoconus and VAE-E groups) with 99.2% specificity among normal eyes. The area under receiver operating characteristic curves (AUROC) of BAD-D was 0.997, which was not significantly lower than the 1 for TBI (AUROC = 1.0) according to DeLong et al⁶⁶ test to compare AUROC. However, the analysis of the separation curves as described by Bühren et al⁶⁷ disclosed a more dichotomous response characteristic of the TBI, which is more tolerant to shifts on the cut-off criterion compared with BAD-D for detecting clinical ectasia.⁵⁹ Nevertheless, the augment of accuracy of the TBI over BAD-D is unblemished when we consider the VAE-NT cases. For those cases, the AUROC of the BAD-D was 0.838 (sensitivity of 80.9% and specificity of 72%), being statistically lower (DeLong, $p < 0.0001$) than the TBI AUROC of 0.985 (sensitivity of 90.4% and specificity of 96%).

This is important to consider that while the TBI had exceeding accuracy over all other parameters tested, there is still a fundamental need for external validations.⁶⁸ Different validation studies have been performed in different countries, including Brazil, Germany, Portugal, US, Italy, Japan, India, and Iran.⁶⁹ A validation study was accomplished in Rio de Janeiro in the same format as the original study for the populations (Mendes et al, submitted data, 2018). In such study, the normal group included one eye randomly selected from 312 patients with normal corneas; keratoconus group included one eye randomly selected from 118 patients with clinical keratoconus in both eyes; the non-operated ectatic eye from 67 patients with very asymmetric ectasia (59 eyes, VAE-E group), and the fellow eye with normal topography (67 eyes, VAE-NT group). The ability for detecting ectasia of TBI was statistically higher than all other tested parameters (AUC comparisons with DeLong, $p < 0.001$). Considering all cases, the cut-off value of 0.33 for the TBI provided 93.4% sensitivity and 94.9% specificity (AUC = 0.982; 95% confidence interval [CI] 0.967–0.993). Considering the VAE-NT group, the same optimized TBI cut-off value of

0.29 provided 86.6% sensitivity and 91% specificity (AUC = 0.939; 95% CI 0.910–0.961). Other studies have demonstrated the clinical validity of the integrated approach with Scheimpflug imaging in relevant case series.⁷⁰

Clinical Example

A 25-year-old patient presented for routine consultation with a peculiar asymmetric keratoconus (Figs 6 to 9). The uncorrected visual acuity (UCVA) was 20/40 + 2 OD and 20/150 OS and DCVA was 20/20 in both eyes with manifest refraction in the right eye of $-2.25 -0.75 \times 40$ and $-2.75 -0.75 \times 75$ in the left eye. The clinical presentation confirms the asymmetry on ectasia; the left eye would not qualify as normal topography even though the Kmax was 44.2D. Interestingly, we have found in different series from 7.2 to 14.4% of the cases with clinical keratoconus to have relatively low keratometric values (Ambrósio et al¹¹). While this case demonstrates that keratoconus may be diagnosed in spite of relatively low keratometric values on corneal topography, the clinical management of this case also deserves consideration. Interestingly, Koller et al⁷¹ reported in a study involving 117 eyes of 99 patients with 1-year follow-up that preoperative DCVA better than 20/25 was identified as a significant risk factor for complications. Thereby, considering DCVA being 20/20 in both eyes, we decided not to indicate cross-linking for this

patient. Patient education emphasized the importance of avoiding eye rubbing and the need for clinical follow-up as previously described.⁷²

ECTASIA SUSCEPTIBILITY AND CONTROVERSIAL ASPECTS OF ECTASIA DIAGNOSIS AND SCREENING

This is imperative to contemplate that ectasia progression after corneal surgery happens because of biomechanical decompensation of corneal stroma, which is related to two unlike factors: The preoperative tendency for ectasia or the biomechanical status of the cornea, and the structural impact from the surgical procedure.¹¹ The impact from the LVC procedure may be evaluated using different parameters including the residual stromal bed and the percent of tissue altered.^{53,73–75} In fact, the current perception is that when screening for ectasia risk among candidates for LVC, the surgeon should consider the procedure the cornea may safely undertake according to the inherent ectasia susceptibility of that given cornea.^{10,11}

In clinical work, screening for ectasia susceptibility involves not just identifying an early or subclinical cases of the disease, but the surgeon should also consider that even a “normal” eye may develop ectasia if stressed beyond a certain biomechanical threshold.^{10,22,29} This is somehow related to the continuum of glaucoma, which

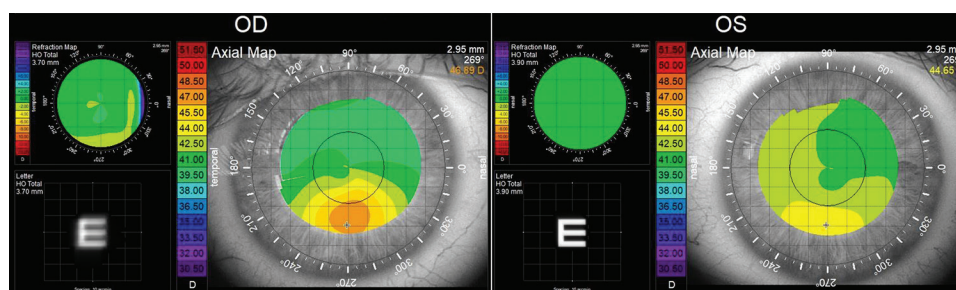

Fig. 6: iTrace Summary (Tracey Technologies; Houston, TX) of a case with mild and asymmetric ectasia

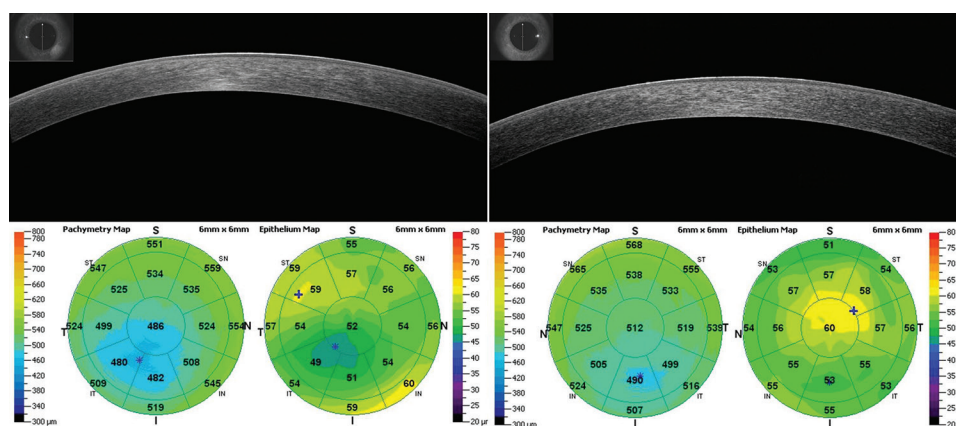


Fig. 7: Segmental tomography from FD-OCT (RTVue) with total pachymetric and epithelial thickness maps limited to 6 mm zone. Note the focal epithelial thinning in the right eye

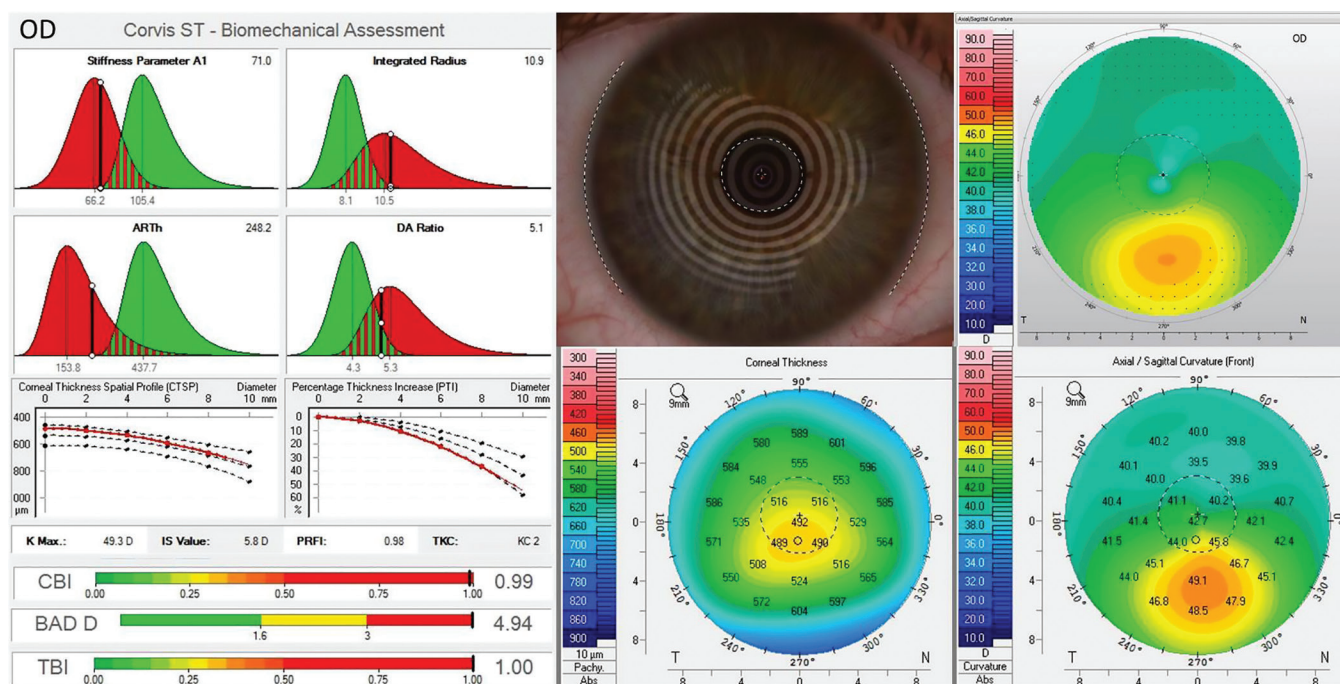


Fig. 8: Composite with the ARV/TBI display (Corvis ST + Pentacam) and the Placido disk-based topography (Keratography 5M) from OD. Note the inferior steepening in the anterior curvature sagittal map in both maps provided by the Placido disk and Scheimpflug devices. Advanced corneal tomographic and biomechanical analysis also revealed abnormal findings

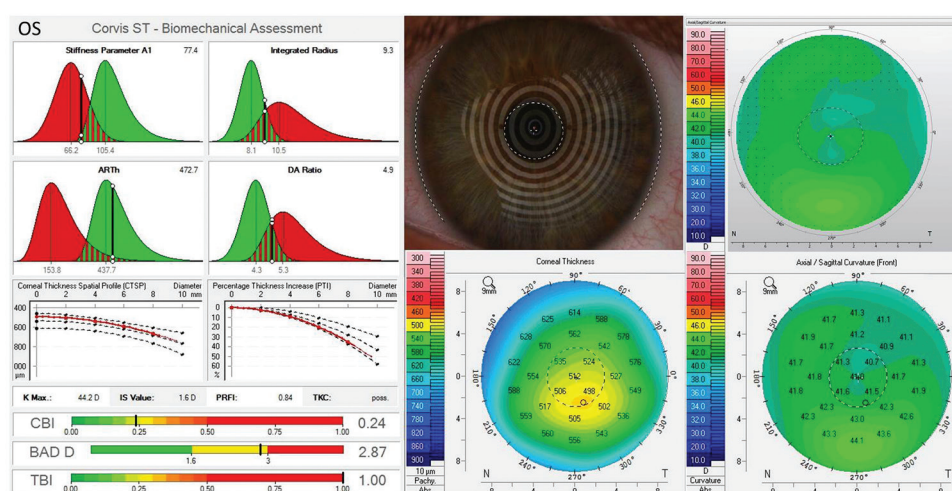


Fig. 9: Composite with the ARV/TBI display (Corvis ST+ Pentacam) and the Placido disk-based topography (Keratography 5M) from OS. Both anterior curvature sagittal maps reveal milder inferior steepening compared with the right eye. The corneal tomographic and biomechanical analyses confirm the presence of abnormal findings consistent with ectasia

has a subsymptomatic phase which may be detected by advanced propedeutics.⁷⁶ Previously, Klyce⁷⁷ referred to the VAE-NT cases as forme fruste keratoconus, a term that was introduced by Marc Amsler⁷⁸ in the early 1960s based on photokeratotomy findings. However, this is important to consider that some of these cases may truly have unilateral disease (Figs 10 and 11).⁷⁹ Curiously, there is a consensus that keratoconus is indeed a bilateral disease, but also that secondary, ectasia may be caused by a pure mechanical process, such as eye rubbing, and this may occur in only one eye.⁴ These ideas are promising with the two-hit hypothesis, which put forward the

notion of ectasia to result from an underlying genetic predisposition along with external or environmental factors, including eye rubbing and atopy.⁵ Our hypothesis is that we need diagnostic metrics, such as the TBI, that epitomize the natural or inherent susceptibility of the cornea to ectasia progression. Beyond the TBI, the hypothesis that segmental tomography with epithelial thickness profile, along with Bowman's layer mapping may further augment accuracy for ectasia detection deserves future studies.³⁶ In addition, ocular wavefront may provide additional relevant data,⁸⁰⁻⁸² along with axial length measurements.^{83,84}

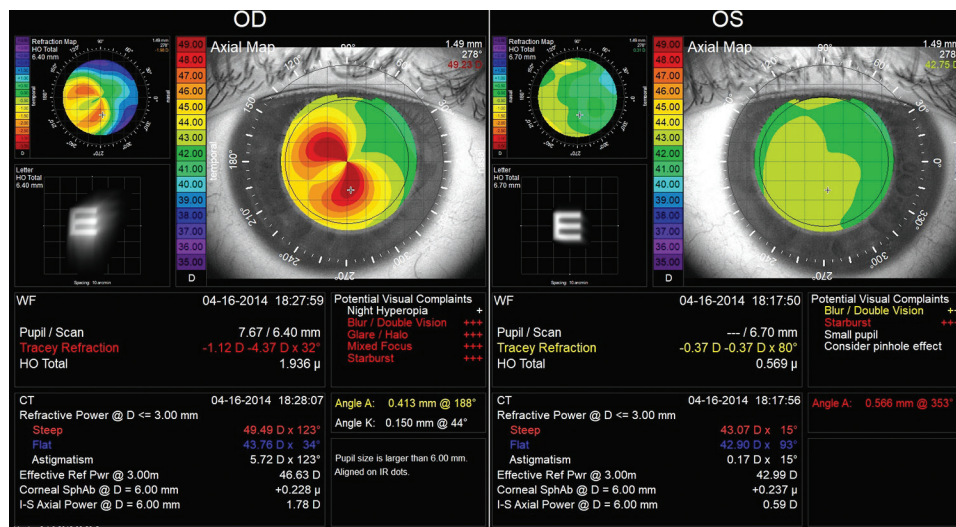


Fig. 10: iTrace Summary with corneal topography and ocular wavefront by ray tracing of individual laser beams from a previously published case of unilateral ectasia OD.⁷⁹ Patient admitted having rubbed only the right eye during early adulthood. The UCVA was 20/20+ in the left eye, considered normal based on all exams including the Gatinel-Saad Score Analyzer (Orbscan; Bausch and Lomb, Rochester, NY),²⁴ and the Artemis (ArcScan; Golden, CO)³²

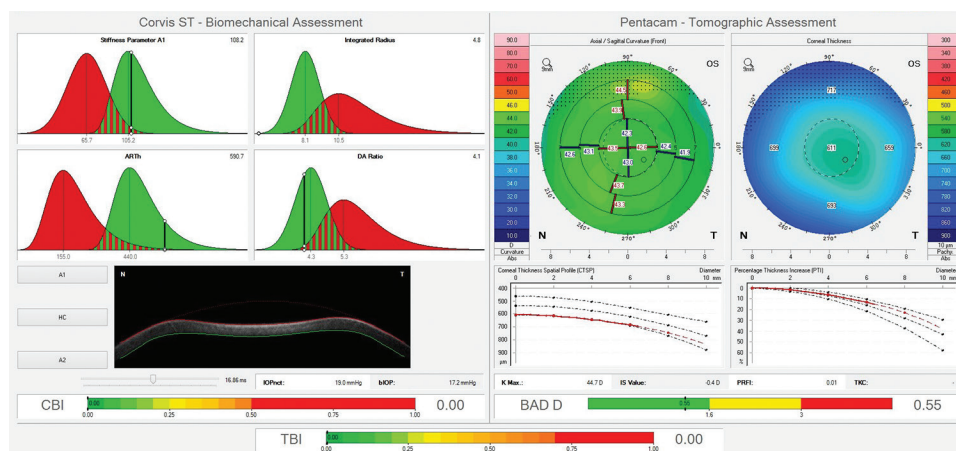


Fig. 11: The ARV Report with integrated Scheimpflug tomography and biomechanics of the same case as in Figure 9

MANAGING ECDs BEGINS WITH EDUCATION

Above and beyond elective refractive surgery, augmenting sensitivity for identifying mild forms of ectasia at early clinical stage and monitoring disease progression have become of utmost importance because of the definitive model or paradigm shift in the management of ECDs, which is related to the introduction of novel therapeutic approaches, such as CXL techniques and ICRS implantation.^{4,5,85} The diagnosis of keratoconus has a significant impact on the life of the patients and their families. Education is the best first line of treatment for the natural fear of going blind. The idea of needing a transplant is because ECD was classically recognized as one of the most common causes of corneal transplantation. In this context, the education of patients and their families about the disease is

indispensable. There are some details that patients deserve to know in order to better live with the disorder. For example, there was a substantial decline in the number of keratoplasty procedures for keratoconus due to the described advances related to the either diagnosis or therapeutics.⁸⁶

For visual rehabilitation, spectacles are the first choice of treatment. Interestingly, a previous study revealed that wavefront-assisted manifest refraction provides a better visual acuity in about 60% of cases with keratoconus.⁸⁷ Special contact lenses fitting is an alternative that also offers optical correction. The selection of the contact lens type depends on the disease stage. For example, the soft lenses with toric design may be adequate for early stages, in order to correct myopia and regular astigmatism. However, the use of contact lenses may increase the risk for ectasia

progression. In more advanced cases, rigid gas permeable or hybrid lenses are preferred. These types of lenses can also correct irregular astigmatism, which enables visual quality improvement. However, there is no evidence to support the fact that use of contact lenses reduces the chances of ectatic progression. It has been shown that similar to the habit of eye rubbing, poorly fitted contact lenses can be associated with disease progression.^{3,86}

The patients should also be informed that keratoconus and ECDs are progressive conditions and require monitoring. As mentioned previously, eye rubbing is directly related to its progression and should be avoided.^{4,5} Therefore, ocular allergic disease management with anti-histamines, mast cell inhibitors along with ocular surface optimization with a dietary supplement of omega-3 fatty acids and preservative-free lubricants are imperative.⁸⁶ Interestingly, recent data have supported the concept of enhancing natural cross-linking with oral supplementation with 400 to 500 mg of riboflavin (vitamin B2) and natural sun exposure for 1/2 hour a day. This anecdote was first reported by Prof Theo Seiler, referring to the experience from the German Air Force ophthalmology that had eliminated the loss of pilots due to keratoconus after implementing a riboflavin-rich diet and demanding the trainee pilots to spend as much as possible time under the sun. While one should be cautious about the dangers of excessive sun exposure to the skin, this is a relatively easy and safe measure that could be taken for patients

with keratoconus, along with the general message to avoid eye rubbing.

Considering these aspects, we decided to launch a patient awareness campaign in Brazil—THE VIOLET JUNE—aiming to raise awareness about the disease as well as educate and spread the message on the risks associated to eye rubbing (Fig. 12). While the year 2018 marks the first year of the campaign, we hope to have this campaign growing every year, starting in June until the 10th of November, when we honor the World Keratoconus Awareness Day, as sponsored by National Keratoconus Foundation of the United States (NKCF—<https://www.nkcf.org/world-kc-day-2017>).

PARADIGM SHIFT IN THE SURGICAL TREATMENT OF CORNEAL ECTATIC DISEASES

The paradigm shift was highlighted by Prof Seiler,⁸⁵ MD, PhD, considering that until the end of the last century (about two decades ago), the treatment of ECD was more unsophisticated and more simple-minded, being limited to spectacles, rigid contacts lens or PKP. Until the mid-1990s, keratoplasty was the only offered surgical option for visual rehabilitation for keratoconus cases. Currently, there are novel procedures, which are less invasive and present as an alternative that should be considered prior to a keratoplasty (Table 1). There are two indications for surgery in cases of keratoconus and ECDs (Table 2). Due to an increasing range of options for surgery in ECDs,

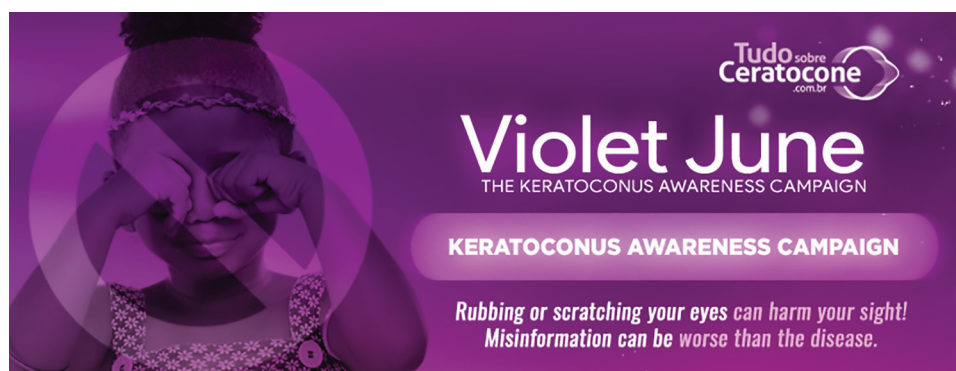

Fig. 12: The VIOLET JUNE: keratoconus awareness campaign

Table 1: Surgical alternatives to corneal transplantation for ectasia

Procedure	Aim
Intracorneal ring segment	Regularization of corneal surface ("tissue add") Reduction of irregular astigmatism
Cross-linking	Stabilization or avoid progression of the disease
Topography-guided photorefractive keratectomy	Regularization of corneal surface ("tissue removal") Reduction of irregular astigmatism
Phakic intraocular lens	Treatment of spherical or spherocylindrical refractive errors (regular astigmatism)
Cataract or refractive lens extraction	Cataract removal, along with treatment of spherical or spherocylindrical refractive errors (regular astigmatism)

The indication with refractive goal should be carefully considered in any case of ectasia

Table 2: Surgery indications in cases with ectatic diseases

<i>Aim</i>	<i>Clinical background/history</i>
Visual improvement	Patient with poor vision corrected by glasses and/or contact lenses
Stabilize the evolution of ectasia	Documented progression of ectasia or evidence of high risk for vision loss

treatment decisions should be based on a precise evaluation of patient needs, medical and anatomical findings, and environmental concerns.^{4,5,86}

Recent therapeutic approaches, such as CXL, have also increased the requirement for an earlier diagnosis of these disorders.^{4,5,86} The advent of CXL determines a new horizon regarding the prevention of disease progression. This procedure is a marginally invasive surgical technique, which combines saturation with riboflavin (vitamin B2) and exposure to ultraviolet (UV) type A (UV-A) to induce cross-links between the collagen fibrils in the corneal stroma. This photochemical reaction involves oxygen consumption. Riboflavin soaking can be performed after epithelial debridement (Epi-off technique).⁸⁸ Alternatively, this procedure can also be done in a transepithelial approach (Epi-on technique), with a different type of riboflavin solutions.⁸⁹ Clinical studies reported that cross-linking declines the progression of the disease, with a decrease in Kmax readings and improvement of the best-corrected visual acuity (BCVA).^{90,91} An age higher than 35 years, a preoperative corrected distance visual acuity higher than 20/25 and high preoperative keratometry readings were identified as significant risk factors for complications and failure of this treatment.^{71,92}

Intracorneal ring segments and topography-guided photorefractive keratectomy (topoguided-PRK), were introduced with the purpose of regularizing the cornea, providing reduction in high-order aberrations.⁸⁵ The advent of femtosecond laser revolutionized anterior segment surgery.⁹³ For example, the dissection technique for implantation of ICRS may be performed manually. However, when it is femtosecond laser-assisted, the postoperative results showed to be more predictable and safer (lower complication rates).^{94,95} During the last years, this surgical procedure underwent some improvements regarding the material and implantation nomograms.^{96,97}

The Athens Protocol is an alternative procedure that aims to regularize corneal shape and halt the progression of ectatic disease. In this procedure, a topoguided-PRK combined with CXL is performed. The ablation pattern should aim to save tissue and is customized to the irregularity of the anterior surface of the cornea. Clinical studies have demonstrated visual acuity and quality improvement derived from the corneal surface regularization, with stabilization of the ectatic disease.⁹⁸⁻¹⁰¹ These procedures may also be combined with phakic

intraocular lens implantation or CXL.^{98,102-108} Differently from original bioptics procedure as described by Zaldivar et al,¹⁰⁹ for refractive surgery in extreme cases of myopia, in which there is an implant of a phakic IOL followed by a LASIK procedure, we propose to name such approaches as Therapeutic Bioptics.¹⁰⁵

In addition, the improvement on surgical techniques and instruments also changed the paradigm of keratoplasty procedures. The PKP consists of a full-thickness replacement of the cornea and was the dominant approach for the majority of causes of corneal blindness for half a century. Interestingly, Von Hippel in 1877, pioneered an innovative procedure in which selective transplantation of corneal stroma without the endothelium, and is the basic perception of the deep anterior lamellar keratoplasty procedure.^{110,111} This surgical technique has become an alternative procedure to PKP in the treatment of different corneal diseases, including keratoconus and ECDs, due to the prevention of intraocular tissue damage, immunologic endothelial rejection/failure and other complications of open-sky surgery, including expulsive hemorrhage. Interestingly, the first studies revealed that PKP had better outcomes of visual acuity, being attributed to the less advanced techniques, such as the manual lamellar dissection. Recently, the Descemet membrane-baring procedure, such as the “big-bubble” and “viscodissection” techniques, provides more efficient visual results.¹¹²⁻¹¹⁷ Despite these improvements in this surgical area, the frequency of keratoplasty for keratoconus and ECD is declining over the last decade. The main reason for this epidemiological finding is the availability of new treatments that allow rapid visual rehabilitation and effective progression control.¹¹⁸

ELECTIVE OR THERAPEUTIC APPROACH

Among the most important considerations when considering surgery for patients with ECD is the proper understanding of therapeutic *vs* refractive elective approaches.^{86,104} In this context, patient and family education are essential for enabling conscious decisions, as well as for setting realistic expectations.

The differences between these approaches must be recognized and taken into account, since the same surgical procedure can present both aims and goals.

For cases with advanced ectasia and elevated magnitudes of high-order aberrations, keratoplasty may be a possible option. Nevertheless, there are less invasive alternatives to keratoplasty for visual rehabilitation. In these contexts, the primary purpose is to provide vision that is correctable by spherocylindrical refraction or even facilitate contact lens fitting. Thus, the measure of success will be related to the improvement in BCVA, the

refractive result being a secondary goal. Considering an elective surgery, the aim is refractive error reduction to provide uncorrected vision and greater independence from spectacles or contact lenses. Thus, the UCVA is the variable that represents the effectiveness of the procedure. However, comparison of the pre- and postoperative corrected visual acuity is always related to the safety of any ophthalmic surgery.

In ECD cases, an elective refractive surgery procedure may be an unconventional alternative for vision correction if glasses or contact lenses enable a satisfactory solution. In such cases, the decision to undergo such procedures should be taken carefully and exclusively by the patient, based on adequate knowledge about the risks, benefits and limitations. The surgeon should focus on the clinical scenario of each case and understand how the correction by using glasses or contact lenses is relatively inadequate and unsatisfactory for the patient. With the evolution of the initial treatment, a case may be proposed for a secondary procedure with an elective refractive purpose. For example, secondary implantation of a phakic intraocular lens has a refractive goal in a patient with DCVA improvement after ICRS implantation. The combination of surgical procedures with different purposes based on the "Therapeutic Bioptics" concept.^{86,105} The informed consent process should be performed with an appropriate explanation to the patient, who must understand the differences between need and possibility, balancing risks, benefits and limitations of the procedure.

CONCLUSION

Keratoconus and ECD comprehend a very hot area for research and clinical interest. Considering the number of articles published over the last years and decades, we expect an increasing number of publications in the subsequent years. We also predict further developments in diagnostic technologies and therapeutics.

Corneal imaging will evolve, including further integration of devices, such as Scheimpflug tomography, OCT segmental tomography, ocular wavefront and biometry, and corneal biomechanical assessment. Considering the vast amount of generated data, the conscious use of AI will play a major role for taking higher advantage of such information for clinical decisions. This is also expected to have an expansion into genetics and molecular biology. While this is acknowledged that the aim for enhanced diagnosis is ultimately to characterize ectasia susceptibility, one should consider that the ideal clinical studies should consider longitudinal data. Prospective well-controlled studies should be designed. Alternatively, retrospective analysis of the preoperative state of cases that developed keratectasia after LASIK should be

consistent model for future studies, also contemplating the surgical impact on the cornea. Another limitation widely seen in studies involving the diagnosis of keratoconus is the group with normal controls. Cases with stable corneas and long follow-up after LVC would provide a more robust population for the normal group. In fact, studies involving such populations enabled the development of the enhanced ectasia susceptibility score.¹¹

In terms of treatments, novel less invasive modalities for CXL are expected to augment safety profile of such procedures and further improve our ability to help patients. Novel intracorneal implants may be designed and customized based on finite element models to add to the armamentarium that includes ICRS, custom therapeutic ablations and phakic IOLs as alternative approaches for keratoplasty. While we predict a bright future for the field of managing ECDs, one should not neglect the focus on patient care, which starts from education and counseling.

ACKNOWLEDGMENTS

Special gratitude to Prof Mark Mannis, MD (UC Davis, Sacramento, CA), who was very generous in sharing Dr John Nottingham's 1854 landmark treatise on Conical Cornea: Nottingham J. Practical Observations on Conical Cornea: And on the Short Sight, and Other Defects of Vision Connected with it. London, United Kingdom: J Churchill; 1854

REFERENCES

1. Gokul A, Patel DV, McGhee CN. Dr John Nottingham's 1854 landmark treatise on conical cornea considered in the context of the current knowledge of keratoconus. *Cornea* 2016 May;35(5):673-678.
2. Grzybowski A, McGhee CN. The early history of keratoconus prior to Nottingham's landmark 1854 treatise on conical cornea: a review. *Clin Exp Optom* 2013 Mar;96(2):140-145.
3. Ambrósio R Jr. Keratoconus and ectatic corneal diseases: are we facing a new subspecialty? *Int J Kerat Ect Dis* 2012 May-Aug;1(2):vii.
4. Gomes JA, Tan D, Rapuano CJ, Belin MW, Ambrósio R Jr, Guell JL, Malecaze F, Nishida K, Sangwan VS; Group of Panelists for the Global Delphi Panel of Keratoconus and Ectatic Diseases. Global consensus on keratoconus and ectatic diseases. *Cornea* 2015 Apr;34(4):359-369.
5. McGhee CN, Kim BZ, Wilson PJ. Contemporary treatment paradigms in keratoconus. *Cornea* 2015 Oct;34(Suppl 10):S16-S23.
6. Ambrósio R Jr, Faria-Correia F, Lopes B, Salomão M, Belin MW. Evolution on keratoconus and corneal ectatic diseases paradigms and paradoxes. *Int J Kerat Ect Cor Dis* 2016 Dec;3:4-7.
7. Torres Netto EA, Al-Otaibi WM, Hafezi NL, Kling S, Al-Farhan HM, Randleman JB, Hafezi F. Prevalence of keratoconus in paediatric patients in Riyadh, Saudi Arabia. *Br J Ophthalmol* 2018 Jan;2018:311391.

8. Wellish KL, Glasgow BJ, Beltran F, Maloney RK. Corneal ectasia as a complication of repeated keratotomy surgery. *J Refract Corneal Surg* 1994 May-Jun;10(3):360-364.
9. Binder PS, Lindstrom RL, Stulting RD, Donnenfeld E, Wu H, McDonnell P, Rabinowitz Y. Keratoconus and corneal ectasia after LASIK. *J Refract Surg* 2005 Nov-Dec;21(6):749-752.
10. Ambrósio R Jr, Randleman JB. Screening for ectasia risk: what are we screening for and how should we screen for it? *J Refract Surg* 2013 Apr;29(4):230-232.
11. Ambrósio R Jr, Belin MW. Enhanced screening for ectasia risk prior to laser vision correction. *Int J Kerat Ect Cor Dis* 2017 Jan-Jun;6(1):23-33.
12. Salomao MQ, Esposito A, Dupps WJ Jr. Advances in anterior segment imaging and analysis. *Curr Opin Ophthalmol* 2009 Jul;20(4):324-332.
13. Ambrósio R Jr, Klyce SD, Wilson SE. Corneal topographic and pachymetric screening of keratorefractive patients. *J Refract Surg* 2003 Jan-Feb;19(1):24-29.
14. Torricelli AA, Bechara SJ, Wilson SE. Screening of refractive surgery candidates for LASIK and PRK. *Cornea* 2014 Oct;33(10):1051-1055.
15. Klein SR, Epstein RJ, Randleman JB, Stulting RD. Corneal ectasia after laser *in situ* keratomileusis in patients without apparent preoperative risk factors. *Cornea* 2006 May;25(4):388-403.
16. Ambrósio R Jr, Dawson DG, Salomao M, Guerra FP, Caiado AL, Belin MW. Corneal ectasia after LASIK despite low preoperative risk: tomographic and biomechanical findings in the unoperated, stable, fellow eye. *J Refract Surg* 2010 Nov;26(11):906-911.
17. Chan CC, Hodge C, Sutton G. External analysis of the Randleman Ectasia Risk Factor Score System: a review of 36 cases of post LASIK ectasia. *Clin Exp Ophthalmol* 2010 May;38(4):335-340.
18. Malecaze F, Couillet J, Calvas P, Fournie P, Arne JL, Brodaty C. Corneal ectasia after photorefractive keratectomy for low myopia. *Ophthalmology* 2006 May;113(5):742-746.
19. Sachdev G, Sachdev MS, Sachdev R, Gupta H. Unilateral corneal ectasia following small-incision lenticule extraction. *J Cataract Refract Surg* 2015 Sep;41(9):2014-2018.
20. Reinstein DZ, Archer TJ, Gobbe M. Stability of LASIK in topographically suspect keratoconus confirmed non-keratoconic by Artemis VHF digital ultrasound epithelial thickness mapping: 1-year follow-up. *J Refract Surg* 2009 Jul;25(7):569-577.
21. Lopes BT, Roberts CJ, Elsheikh A, Vinciguerra R, Vinciguerra P, Reisdorf S, Berger S, Koprowski R, Ambrósio R Jr. Repeatability and reproducibility of intraocular pressure and dynamic corneal response parameters assessed by the Corvis ST. *J Ophthalmol* 2017 Jun;2017:8515742.
22. Ambrósio R Jr, Nogueira LP, Caldas DL, Fontes BM, Luz A, Cazal JO, Alves MR, Belin MW. Evaluation of corneal shape and biomechanics before LASIK. *Int Ophthalmol Clin* 2011 Spring;51(2):11-38.
23. Ambrósio R Jr, Belin MW. Imaging of the cornea: topography vs tomography. *J Refract Surg* 2010 Nov;26(11):847-849.
24. Saad A, Gatineau D. Topographic and tomographic properties of forme fruste keratoconus corneas. *Invest Ophthalmol Vis Sci* 2010 Nov;51(11):5546-5555.
25. Ambrósio R Jr, Valbon BF, Faria-Correia F, Ramos I, Luz A. Scheimpflug imaging for laser refractive surgery. *Curr Opin Ophthalmol* 2013 Jul;24(4):310-320.
26. Smadja D, Touboul D, Cohen A, Doveh E, Santhiago MR, Mello GR, Krueger RR, Colin J. Detection of subclinical keratoconus using an automated decision tree classification. *Am J Ophthalmol* 2013 Aug;156(2):237.e1-246.e1.
27. Belin MW, Ambrósio R. Scheimpflug imaging for keratoconus and ectatic disease. *Indian J Ophthalmol* 2013 Aug;61(8):401-406.
28. Lopes BT, Ramos IC, Dawson DG, Belin MW, Ambrósio R Jr. Detection of ectatic corneal diseases based on pentacam. *Z Med Phys* 2016 Jun;26(2):136-142.
29. Ambrósio R Jr, Ramos I, Lopes B, Canedo AL, Correa R, Guerra F, Luz A, Price FW Jr, Price MO, Schallhorst S, et al. Assessing ectasia susceptibility prior to LASIK: the role of age and residual stromal bed (RSB) in conjunction to Belin-Ambrósio deviation index (BAD-D). *Rev Bras Oftalmol* 2014 Mar-Apr;73(2):75-80.
30. Li Y, Tan O, Brass R, Weiss JL, Huang D. Corneal epithelial thickness mapping by Fourier-domain optical coherence tomography in normal and keratoconic eyes. *Ophthalmology* 2012 Dec;119(12):2425-2433.
31. Reinstein DZ, Gobbe M, Archer TJ, Silverman RH, Coleman DJ. Epithelial, stromal, and total corneal thickness in keratoconus: three-dimensional display with artemis very-high frequency digital ultrasound. *J Refract Surg* 2010 Apr;26(4):259-271.
32. Silverman RH, Urs R, Roychoudhury A, Archer TJ, Gobbe M, Reinstein DZ. Epithelial remodeling as basis for machine-based identification of keratoconus. *Invest Ophthalmol Vis Sci* 2014 Mar;55(3):1580-1587.
33. Pahuja N, Shroff R, Pahanpate P, Francis M, Veeboy L, Shetty R, Nuijts RM, Sinha Roy A. Application of high resolution OCT to evaluate irregularity of Bowman's layer in asymmetric keratoconus. *J Biophotonics* 2017 May;10(5):701-707.
34. Reinstein DZ, Archer TJ, Gobbe M. Corneal epithelial thickness profile in the diagnosis of keratoconus. *J Refract Surg* 2009 Jul;25(7):604-610.
35. Li Y, Chamberlain W, Tan O, Brass R, Weiss JL, Huang D. Subclinical keratoconus detection by pattern analysis of corneal and epithelial thickness maps with optical coherence tomography. *J Cataract Refract Surg* 2016 Feb;42(2):284-295.
36. Salomao MQ, Hofling-Lima AL, Lopes BT, Canedo AL, Dawson DG, Carneiro-Freitas R, Ambrósio R Jr. Role of the corneal epithelium measurements in keratorefractive surgery. *Curr Opin Ophthalmol* 2017 Jul;28(4):326-336.
37. Roberts CJ, Dupps WJ Jr. Biomechanics of corneal ectasia and biomechanical treatments. *J Cataract Refract Surg* 2014 Jun;40(6):991-998.
38. Luce DA. Determining *in vivo* biomechanical properties of the cornea with an ocular response analyzer. *J Cataract Refract Surg* 2005 Jan;31(1):156-162.
39. Fontes BM, Ambrósio R Jr, Jardim D, Velarde GC, Nose W. Corneal biomechanical metrics and anterior segment parameters in mild keratoconus. *Ophthalmology* 2010 Apr;117(4):673-679.
40. Luz A, Lopes B, Hallahan KM, Valbon B, Fontes B, Schor P, Dupps WJ Jr, Ambrósio R Jr. Discriminant value of custom ocular response analyzer waveform derivatives in forme fruste keratoconus. *Am J Ophthalmol* 2016 Apr;164:14-21.
41. Luz A, Lopes B, Hallahan KM, Valbon B, Ramos I, Faria-Correia F, Schor P, Dupps WJ Jr, Ambrósio R Jr. Enhanced combined tomography and biomechanics data for distinguishing forme fruste keratoconus. *J Refract Surg* 2016 Jul;32(7):479-494.

42. Ambrósio R Jr, Ramos I, Luz A, Correia Faria F, Steinmueller A, Krug M, Belin MW, Roberts CJ. Dynamic Ultra-High Speed Scheimpflug Imaging for assessing corneal biomechanical properties. *Rev Bras Oftalmol* 2013 Mar-Apr;72(2):99-102.
43. Ali NQ, Patel DV, McGhee CN. Biomechanical responses of healthy and keratoconic corneas measured using a noncontact Scheimpflug-based tonometer. *Invest Ophthalmol Vis Sci* 2014 May;55(6):3651-3659.
44. Bak-Nielsen S, Pedersen IB, Ivarsen A, Hjortdal J. Dynamic Scheimpflug-based assessment of keratoconus and the effects of corneal cross-linking. *J Refract Surg* 2014 Jun;30(6):408-414.
45. Steinberg J, Katz T, Lucke K, Frings A, Druchkiv V, Linke SJ. Screening for keratoconus with new dynamic biomechanical *in vivo* Scheimpflug analyses. *Cornea* 2015 Nov;34(11):1404-1412.
46. Ambrósio R Jr, Lopes B, Faria-Correia F, Vinciguerra R, Vinciguerra P, Elsheikh A, Roberts CJ. Ectasia detection by the assessment of corneal biomechanics. *Cornea* 2016 Jul;35(7):e18-e20.
47. Vinciguerra R, Elsheikh A, Roberts CJ, Ambrósio R Jr, Kang DS, Lopes BT, Morengi E, Azzolini C, Vinciguerra P. Influence of pachymetry and intraocular pressure on dynamic corneal response parameters in healthy patients. *J Refract Surg* 2016 Aug;32(8):550-561.
48. Vinciguerra R, Ambrósio R Jr, Elsheikh A, Roberts CJ, Lopes B, Morengi E, Azzolini C, Vinciguerra P. Detection of keratoconus with a new biomechanical index. *J Refract Surg* 2016 Dec;32(12):803-810.
49. Lopes BT, Ramos IC, Salomão MQ, Canedo AL, Ambrósio R Jr. Perfil paquimétrico horizontal para a detecção do ceratocone. *Rev Bras Oftalmol* 2015 Nov-Dec;74(6):383-385.
50. Joda AA, Shervin MM, Kook D, Elsheikh A. Development and validation of a correction equation for Corvis tonometry. *Comput Methods Biomech Biomed Eng* 2016;19(9):943-953.
51. Eliasy A, Chen KJ, Vinciguerra R, Maklad O, Vinciguerra P, Ambrósio R Jr, Roberts CJ, Elsheikh A. *Ex-vivo* experimental validation of biomechanically-corrected intraocular pressure measurements on human eyes using the CorVis ST. *Exp Eye Res* 2018 Jun;175:98-102.
52. Chen KJ, Joda A, Vinciguerra R, Eliasy A, Sefat SM, Kook D, Geraghty B, Roberts CJ, Elsheikh A. Clinical evaluation of a new correction algorithm for dynamic Scheimpflug analyzer tonometry before and after laser *in situ* keratomileusis and small-incision lenticule extraction. *J Cataract Refract Surg* 2018 May;44(5):581-588.
53. Ambrósio R Jr, Dawson DG, Belin MW. Association between the percent tissue altered and post-laser *in situ* keratomileusis ectasia in eyes with normal preoperative topography. *Am J Ophthalmol* 2014 Dec;158(6):1358-1359.
54. Arbelaez MC, Versaci F, Vestri G, Barboni P, Savini G. Use of a support vector machine for keratoconus and subclinical keratoconus detection by topographic and tomographic data. *Ophthalmology* 2012 Nov;119(11):2231-2238.
55. Muftuoglu O, Ayar O, Ozulken K, Ozyol E, Akinci A. Posterior corneal elevation and back difference corneal elevation in diagnosing forme fruste keratoconus in the fellow eyes of unilateral keratoconus patients. *J Cataract Refract Surg* 2013 Sep;39(9):1348-1357.
56. Shetty R, Rao H, Khamar P, Sainani K, Vunnavu K, Jayadev C, Kaweri L. Keratoconus screening indices and their diagnostic ability to distinguish normal from ectatic corneas. *Am J Ophthalmol* 2017 Sep;181:140-148.
57. Vinciguerra R, Ambrósio R Jr, Roberts CJ, Azzolini C, Vinciguerra P. Biomechanical characterization of subclinical keratoconus without topographic or tomographic abnormalities. *J Refract Surg* 2017 Jun;33(6):399-407.
58. Reinstein DZ, Archer TJ, Urs R, Gobbe M, Roy Choudhury A, Silverman RH. Detection of keratoconus in clinically and algorithmically topographically normal fellow eyes using epithelial thickness analysis. *J Refract Surg* 2015 Nov;31(11):736-744.
59. Ambrósio R Jr, Lopes BT, Faria-Correia F, Salomão MQ, Bühren J, Roberts CJ, Elsheikh A, Vinciguerra R, Vinciguerra P. Integration of Scheimpflug-based corneal tomography and biomechanical assessments for enhancing ectasia detection. *J Refract Surg* 2017 Jul;33(7):434-443.
60. Rabinowitz YS. Keratoconus. *Surv Ophthalmol* 1998 Jan-Feb;42(4):297-319.
61. Rabinowitz YS, Rasheed K. KISA% index: a quantitative videokeratography algorithm embodying minimal topographic criteria for diagnosing keratoconus. *J Cataract Refract Surg* 1999 Oct;25(10):1327-1335.
62. Ramos IC, Correa R, Guerra FP, Trattler W, Belin MW, Klyce SD, Fontes BM, Schor P, Smolek MK, Dawson DG, et al. Variability of subjective classifications of corneal topography maps from LASIK candidates. *J Refract Surg* 2013 Nov;29(11):770-775.
63. Ambrósio R Jr, Luz A, Lopes B, Ramos I, Belin MW. Enhanced ectasia screening: the need for advanced and objective data. *J Refract Surg* 2014 Mar;30(3):151-152.
64. Ambrósio R Jr, Ramos I, Lopes B, Santhiago MR, Faria-Correia F, Belin M, Binder PS. Ectasia susceptibility before laser vision correction. *J Cataract Refract Surg* 2015 Jun;41(6):1335-1336.
65. Belin MW, Villavicencio OF, Ambrósio R Jr. Tomographic parameters for the detection of keratoconus: suggestions for screening and treatment parameters. *Eye Contact Lens* 2014 Nov;40(6):326-330.
66. DeLong ER, DeLong DM, Clarke-Pearson DL. Comparing the areas under two or more correlated receiver operating characteristic curves: a nonparametric approach. *Biometrics* 1988 Sep;44(3):837-845.
67. Bühren J, Kuhne C, Kohnen T. Defining subclinical keratoconus using corneal first-surface higher-order aberrations. *Am J Ophthalmol* 2007 Mar;143(3):381-389.
68. Lopes B, Ramos IC, Ribeiro G, Correa R, Valbon BF, da Luiz AC, Salomao M, Lyra JM, Ambrósio R Jr. Bioestatísticas: conceitos fundamentais e aplicações práticas. *Rev Bras Oftalmol* 2014;73(1):16-22.
69. Ambrósio R Jr.; Padmanabhan, P.; Momeni-Moghaddam, H. Integrated Scheimpflug corneal tomography & biomechanics for enhanced ectasia detection: the TBI study & external validations. New Orleans (LA): ISRS/AAO; 2017.
70. Haddad JS, Barnwell E, Rocha KM, Waring GO IV, Ambrósio R Jr. First clinical impressions on the integrated corneal tomography and corneal deformation with scheimpflug imaging. *Int J Kerat Ect Cor Dis* 2017 Jul-Dec;6(2):101-109.
71. Koller T, Mrochen M, Seiler T. Complication and failure rates after corneal crosslinking. *J Cataract Refract Surg* 2009 Aug;35(8):1358-1362.
72. de Oliveira Correa R, Canedo AL, Beildeck R, Salomão MQ, de Politis PB, Ambrósio R Jr. Longterm stability of ectasia in a young patient with asymmetric keratoconus. *Int J Kerat Ect Cor Dis* 2015 May-Aug;4(2):66-68.

73. Santhiago MR, Smadja D, Wilson SE, Krueger RR, Monteiro ML, Randleman JB. Role of percent tissue altered on ectasia after LASIK in eyes with suspicious topography. *J Refract Surg* 2015 Apr;31(4):258-265.
74. Santhiago MR, Smadja D, Gomes BF, Mello GR, Monteiro ML, Wilson SE, Randleman JB. Association between the percent tissue altered and post-laser *in situ* keratomileusis ectasia in eyes with normal preoperative topography. *Am J Ophthalmol* 2014 Jul;158(1):87.e1-95.e1.
75. Ambrósio R Jr, Wilson SE. Complications of laser *in situ* keratomileusis: etiology, prevention, and treatment. *J Refract Surg* 2001 May-Jun;17(3):350-379.
76. Abe RY, Diniz-Filho A, Zangwill LM, Gracitelli CP, Marvasti AH, Weinreb RN, Baig S, Medeiros FA. The relative odds of progressing by structural and functional tests in glaucoma. *Invest Ophthalmol Vis Sci* 2016 Jul;57(9):OCT421-OCT428.
77. Klyce SD. Chasing the suspect: keratoconus. *Br J Ophthalmol* 2009 Jul;93(7):845-847.
78. Amsler M. [The "forme fruste" of keratoconus]. *Wien Klin Wochenschr* 1961 Dec;73:842-843.
79. Ramos IC, Reinsteinst DZ, Archer TJ, Gobbe M, Salomao MQ, Lopes B, Luz A, Faria-Correia F, Gatineau D, Belin MW, et al. Unilateral ectasia characterized by advanced diagnostic tests. *Int J Ker Ect Cor Dis* 2016 Jan-Apr;5(1):40-51.
80. Saad A, Gatineau D. Combining placido and corneal wavefront data for the detection of forme fruste keratoconus. *J Refract Surg* 2016 Aug;32(8):510-516.
81. Rabinowitz YS, Li X, Canedo AL, Ambrósio R Jr, Bykhovskaya Y. Optical coherence tomography combined with videokeratography to differentiate mild keratoconus subtypes. *J Refract Surg* 2014 Feb;30(2):80-87.
82. Jafri B, Li X, Yang H, Rabinowitz YS. Higher order wavefront aberrations and topography in early and suspected keratoconus. *J Refract Surg* 2007 Oct;23(8):774-781.
83. Yagci R, Guler E, Kulak AE, Erdogan BD, Balci M, Hepsen IF. Repeatability and reproducibility of a new optical biometer in normal and keratoconic eyes. *J Cataract Refract Surg* 2015 Jan;41(1):171-177.
84. Sahebzada S, Xie J, Chan E, Snibson G, Daniel M, Baird PN. Assessment of anterior segment parameters of keratoconus eyes in an Australian population. *Optom Vis Sci* 2014 Jul;91(7):803-809.
85. Seiler T. The paradigm change in keratoconus therapy. *Indian J Ophthalmol* 2013 Aug;61(8):381.
86. Faria-Correia F, Luz A, Ambrósio R Jr. Managing corneal ectasia prior to keratoplasty. *Expert Rev Ophthalmol* 2015 Jan;10(1):33-48.
87. Ambrósio R Jr, Caldas DL, Silva RS, Pimentel LN, Valbon BF. Impacto da análise do "wavefront" na refractometria de pacientes com ceratocone. *Rev Bras Oftalmol* 2010 Sep-Oct;69(5):294-300.
88. Wollensak G, Spoerl E, Seiler T. Riboflavin/ultraviolet-a-induced collagen crosslinking for the treatment of keratoconus. *Am J Ophthalmol* 2003 May;135(5):620-627.
89. Mastropasqua L, Nubile M, Caliendo R, Mattei PA, Pedrotti E, Salgari N, Mastropasqua R, Lanzini M. Corneal cross-linking: intrastromal riboflavin concentration in iontophoresis-assisted imbibition versus traditional and transepithelial techniques. *Am J Ophthalmol* 2014 Mar;157(3):623.e1-630.e1.
90. Caporossi A, Mazzotta C, Baiocchi S, Caporossi T. Long-term results of riboflavin ultraviolet a corneal collagen cross-linking for keratoconus in Italy: the Siena eye cross study. *Am J Ophthalmol* 2010 Apr;149(4):585-593.
91. Vinciguerra P, Albe E, Trazza S, Rosetta P, Vinciguerra R, Seiler T, Epstein D. Refractive, topographic, tomographic, and aberrometric analysis of keratoconic eyes undergoing corneal cross-linking. *Ophthalmology* 2009 Mar;116(3):369-378.
92. Seiler TG, Schmidinger G, Fischinger I, Koller T, Seiler T. Complications of corneal cross-linking. *Ophthalmologie* 2013 Jul;110(7):639-644.
93. Ambrósio R Jr. A revolução dos lasers de femtossegundo na oftalmologia. *Rev Bras Oftalmol* 2011 Jul-Aug;70(4):207-210.
94. Pinero DP, Alio JL. Intracorneal ring segments in ectatic corneal disease—a review. *Clin Exp Ophthalmol* 2010 Mar;38(2):154-167.
95. Pinero DP, Alio JL, El Kady B, Coskunseven E, Morbelli H, Uceda-Montanes A, Maldonado MJ, Cuevas D, Pascual I. Refractive and aberrometric outcomes of intracorneal ring segments for keratoconus: mechanical versus femtosecond-assisted procedures. *Ophthalmology* 2009 Sep;116(9):1675-1687.
96. Alfonso JF, Fernandez-Vega Cueto L, Baamonde B, Merayo-Llodes J, Madrid-Costa D, Montes-Mico R. Inferior intrastromal corneal ring segments in paracentral keratoconus with no coincident topographic and coma axis. *J Refract Surg* 2013 Apr;29(4):266-272.
97. Alfonso JF, Lisa C, Merayo-Llodes J, Fernandez-Vega Cueto L, Montes-Mico R. Intrastromal corneal ring segment implantation in paracentral keratoconus with coincident topographic and coma axis. *J Cataract Refract Surg* 2012 Sep;38(9):1576-1582.
98. Kanellopoulos AJ. Comparison of sequential vs same-day simultaneous collagen cross-linking and topography-guided PRK for treatment of keratoconus. *J Refract Surg* 2009 Sep;25(9):S812-S818.
99. Kanellopoulos AJ, Asimellis G. Keratoconus management: long-term stability of topography-guided normalization combined with high-fluence CXL stabilization (the Athens Protocol). *J Refract Surg* 2014 Feb;30(2):88-93.
100. Kanellopoulos AJ, Binder PS. Management of corneal ectasia after LASIK with combined, same-day, topography-guided partial transepithelial PRK and collagen cross-linking: the Athens protocol. *J Refract Surg* 2011 May;27(5):323-331.
101. Kanellopoulos AJ, Binder PS. Collagen cross-linking (CCL) with sequential topography-guided PRK: a temporizing alternative for keratoconus to penetrating keratoplasty. *Cornea* 2007 Aug;26(7):891-895.
102. Krueger RR, Kanellopoulos AJ. Stability of simultaneous topography-guided photorefractive keratectomy and riboflavin/UVA cross-linking for progressive keratoconus: case reports. *J Refract Surg* 2010 Oct;26(10):S827-S832.
103. Koller T, Iseli HP, Donitzky C, Ing D, Papadopoulos N, Seiler T. Topography-guided surface ablation for forme fruste keratoconus. *Ophthalmology* 2006 Dec;113(12):2198-2202.
104. Ambrósio R Jr. Cirurgia refrativa terapêutica: por que diferenciar? *Rev Bras Oftalmol* 2013 Mar-Apr;72(2):85-86.
105. Ambrósio R Jr. Intracorneal ring segment, phakic IOL implantation enable keratoconus management without keratoplasty. *Ocul Surg News US Edition*; 2011. [cited 2011 Dec 10]. Available from: <http://www.healio.com/ophthalmology/cornea-external-disease/news/print/ocular-surgery-news/%7B%26ba6e3-e6db-47e6-8b6a-b53bdcd7f33a%7D/intracorneal-ring-segment-phakic-iol-implantation-enable-keratoconus-management-without-keratoplasty>.

106. Ramirez-Miranda A, Jaimes M, Graue-Hernandez EO, Ramirez-Luquin T, Navas A. Toric intraocular lens in keratoconus. *Cornea* 2012 Mar;31(3):335-336.
107. Kymionis GD. Corneal collagen cross linking—PLUS. *Open Ophthalmol J* 2011 Feb;5:10.
108. Kymionis GD, Grentzelos MA, Portaliou DM, Kankariya VP, Randleman JB. Corneal collagen cross-linking (CXL) combined with refractive procedures for the treatment of corneal ectatic disorders: CXL plus. *J Refract Surg* 2014 Aug;30(8):566-576.
109. Zaldivar R, Davidorf JM, Oscherow S, Ricur G, Piezzi V. Combined posterior chamber phakic intraocular lens and laser *in situ* keratomileusis: bioptics for extreme myopia. *J Refract Surg* 1999 May-Jun;15(3):299-308.
110. Luz A, Babosa L, Fontes BM, Ramos I, Schor P, Ambrósio R Jr. Deep Anterior Lamellar Keratoplasty for Ectatic Disease. *Int J Kerat Ect Cor Dis* 2013;2(1):20-27.
111. Parker JS, van Dijk K, Melles GR. Treatment options for advanced keratoconus: a review. *Surv Ophthalmol* 2015 Sep-Oct;60(5):459-480.
112. Anwar M, Teichmann KD. Big-bubble technique to bare Descemet's membrane in anterior lamellar keratoplasty. *J Cataract Refract Surg* 2002 Mar;28(3):398-403.
113. Melles GR, Lander F, Rietveld FJ, Remeijer L, Beekhuis WH, Binder PS. A new surgical technique for deep stromal, anterior lamellar keratoplasty. *Br J Ophthalmol* 1999 Mar;83(3):327-333.
114. Huang T, Hu Y, Gui M, Hou C, Zhang H. Comparison of refractive outcomes in three corneal transplantation techniques for keratoconus. *Graefes Arch Clin Exp Ophthalmol* 2015 Nov;253(11):1947-1953.
115. Kim KH, Choi SH, Ahn K, Chung ES, Chung TY. Comparison of refractive changes after deep anterior lamellar keratoplasty and penetrating keratoplasty for keratoconus. *Jpn J Ophthalmol* 2011 Mar;55(2):93-97.
116. Cohen AW, Goins KM, Sutphin JE, Wandling GR, Wagoner MD. Penetrating keratoplasty versus deep anterior lamellar keratoplasty for the treatment of keratoconus. *Int Ophthalmol* 2010 Dec;30(6):675-681.
117. Shimazaki J, Shimmura S, Ishioka M, Tsubota K. Randomized clinical trial of deep lamellar keratoplasty vs penetrating keratoplasty. *Am J Ophthalmol* 2002 Aug;134(2):159-165.
118. Sandvik GF, Thorsrud A, Raen M, Ostern AE, Saethre M, Drolsum L. Does corneal collagen cross-linking reduce the need for keratoplasties in patients with keratoconus? *Cornea* 2015 Sep;34(9):991-995.