

# To evaluate the Role and Efficacy of Collagen Cross-linkage with Ultraviolet Therapy following Riboflavin Drops with Orbscan in Cases of Progressive Keratoconus

<sup>1</sup>Parmod Guleria, <sup>2</sup>Vikas Sharma

## ABSTRACT

**Aim:** To evaluate the role and efficacy of collagen cross-linkage with riboflavin (C3R) in cases of progressive keratoconus.

**Study design:** Prospective, nonrandomized, single-center clinical study.

**Materials and methods:** The C3R was done in 32 eyes of 21 patients with at least 6 months of documented progression. Outcome of the procedure was measured by means of uncorrected visual acuity (UCVA), best spectacle corrected visual acuity (BSCVA), corneal topography with Orbscan changes in posterior best fit sphere (PBFS), ratio of anterior and posterior best fit sphere (ABFS/PBFS), astigmatic changes in central 3- and 5-mm zone, central endothelial count postcorneal C3R.

**Results:** Thirty-two eyes with a follow-up of 6 months were analyzed. The mean age was 19.8 years. The preoperative values on the day of treatment were compared with postoperative values after the 6-month examination. The improvement in UCVA and BSCVA was statistically significant ( $p = 0.02$  and  $0.01$  respectively). The change in power for PBFS was not statistically significant ( $p = -0.08$ ). There was no significant difference in corneal endothelial counts pre- and post-C3R ( $p = 0.058$ ). Mean value pre-C3R for ratio of ABFS/PBFS was  $1.25 \pm 3.7$  and post-C3R was  $1.22 \pm 1.8$  ( $p = 0.00$ ). Mean value of astigmatism in 3-mm zone pre- and post-C3R was  $-4.3 \pm 0.98$  and  $-3.9 \pm 0.66$  ( $p = 0.046$ ) respectively. Mean value pre-C3R for astigmatism in 5-mm zone was  $-4.9 \pm 1.91$  and post-C3R was  $-4.0 \pm 0.82$  ( $p = 0.02$ ).

**Conclusion:** The results show a stabilization and improvement in keratoconus after C3R in Indian eyes.

**Keywords:** Astigmatism, Collagen corneal cross-linking, Keratoconus, Orbscan.

**How to cite this article:** Guleria P, Sharma V. To evaluate the Role and Efficacy of Collagen Cross-linkage with Ultraviolet Therapy following Riboflavin Drops with Orbscan in Cases of Progressive Keratoconus. *Int J Kerat Ect Cor Dis* 2017;6(2):67-72.

**Source of support:** Nil

**Conflict of interest:** None

<sup>1</sup>Registrar, <sup>2</sup>Resident

<sup>1</sup>Department of Ophthalmology, Indira Gandhi Medical College Shimla, Himachal Pradesh, India

<sup>2</sup>Department of Ophthalmology, 7 Air Force Hospital, Kanpur Uttar Pradesh, India

**Corresponding Author:** Vikas Sharma, Resident, Department of Ophthalmology, 7 Air Force Hospital, Kanpur, Uttar Pradesh, India  
Phone: +915122380173, e-mail: vikas.sharmadr@gmail.com

## INTRODUCTION

Keratoconus is a slowly progressive, noninflammatory corneal dystrophy characterized by changes in corneal collagen structure and organization.<sup>1,2</sup> A reduced number of C3Rs and a pepsin digestion higher than normal induce an overall structural weakness of the corneal tissue, resulting in a stiffness that is 60% that of normal cornea.<sup>3</sup> Decreased mechanical corneal stability plays an important role in the progressive protrusion of keratoconic cornea, resulting in mild-to-marked impairment of visual acuity owing to irregular astigmatism, progressive myopia, corneal thinning, and corneal scarring.<sup>4</sup> The clinical diagnosis of moderate-to-advanced keratoconus can be made because of characteristic topographic pattern and the classical signs. However, diagnosing early keratoconus in patients with normal best BSCVA and minimum or no clinical signs can be challenging.<sup>5</sup>

On retinoscopy, keratoconus is among the ophthalmic conditions that exhibit a scissor reflex action of two bands moving toward and away from each other like the blades of a pair of scissors.<sup>6</sup> Scarring appears to be an aspect of the corneal degradation; however, a recent, large, multicenter study suggests that abrasion by contact lenses may increase the likelihood of this finding by a factor of over 2.<sup>7</sup>

A number of studies have indicated that keratoconic corneas show signs of increased activity by proteases, a class of enzymes that break some of the collagen cross-linkages in the stroma, with a simultaneous reduced expression of protease inhibitors.<sup>8</sup> While keratoconus is considered a noninflammatory disorder, one study shows that rigid contact lens wear by patients leads to overexpression of proinflammatory cytokines, such as interleukin 6, tumor necrosis factor alpha, intercellular adhesion molecule-1, and vascular cell adhesion molecule-1 in the tear fluid.<sup>9</sup>

Corneal collagen cross-linking with riboflavin is the name given to the treatment that combines the use of riboflavin (vitamin B2) with ultraviolet (UV) light for the treatment of keratoconus. The riboflavin 0.1% eye drops in 20% dextran are activated by approximately 30 minutes illumination with UVA (370 nm) light. This treatment is applied to de-epithelialized cornea. The

currently used UVA radiant exposure of 5.4 mJ/cm<sup>2</sup> and the corresponding irradiance of 3 mW/cm<sup>2</sup> are below the known damage thresholds of UVA for the corneal endothelium, lens, and retina.<sup>10</sup>

Exposing riboflavin to UVA light promotes its photo-mediator properties and extends the effects of the irradiation to the surrounding tissue. Following exposure, riboflavin is excited into a triplet state, thereby generating reactive oxygen species, singlet oxygen, and superoxide anions. These then act to induce the formation of new covalent bonds between the amino acids of neighboring collagen fibers.<sup>11</sup> The wavelength of 370 nm is used to achieve maximal absorption by the riboflavin, while remaining below harmful deoxyribonucleic acid and retinal radiation levels.<sup>10</sup> The technique of C3R consists of photopolymerization of stromal fibers by the combined action of a photosensitizing substance (riboflavin or vitamin B2) and UVA rays from a solid-state UVA source.<sup>12</sup> The C3R augments the collagen cross-links within the stroma and so recovers some of the cornea's mechanical strength.<sup>12</sup> Photopolymerization increases the rigidity of corneal collagen and its resistance to keratectasia.<sup>13</sup> The cross-linking effect is not distributed homogeneously over the corneal depth. The stiffening effect is concentrated in the anterior 200 to 300 μm of the cornea due to the high absorption of UV light in this area.<sup>13</sup>

The aim of this prospective nonrandomized study was to show the results of riboflavin UVA-induced C3R in an Indian cohort of patients affected by progressive keratoconus, after 1 year of follow-up.

## MATERIALS AND METHODS

This study was conducted at the Department of Ophthalmology, Army Hospital (Research and Referral), Delhi Cantonment, New Delhi, India. Thirty-two eyes of 21 patients, having progressive keratoconus based on corneal topography, were enrolled from September 2009 to September 2010.

This study included patients with documented progressive keratoconus over a period of 6 months based on corneal topography. Other inclusion criteria included central corneal thickness of at least 400 μm, age between 16 and 60 years, and no evidence of corneal scarring on slit-lamp examination.

Exclusion criteria include patients having a history of herpetic keratitis, severe dry eye, concurrent corneal infections, concomitant autoimmune disease, patients with any previous ocular surgery, pregnant or nursing women, patients with central or paracentral opacities, patients wearing rigid gas-permeable lenses for more than 6 weeks, and patients with poor compliance.

Progressive keratoconus was generally accepted as 1 dioptre (D) increase in the power of cone per year, an

increase in maximum keratometry (K) of 1.00 D in 1 year, patient reports of deteriorating BCVA (excluding other possible noncornea-related reasons for deterioration), or the need for new contact lens fitting more than once in 2 years.

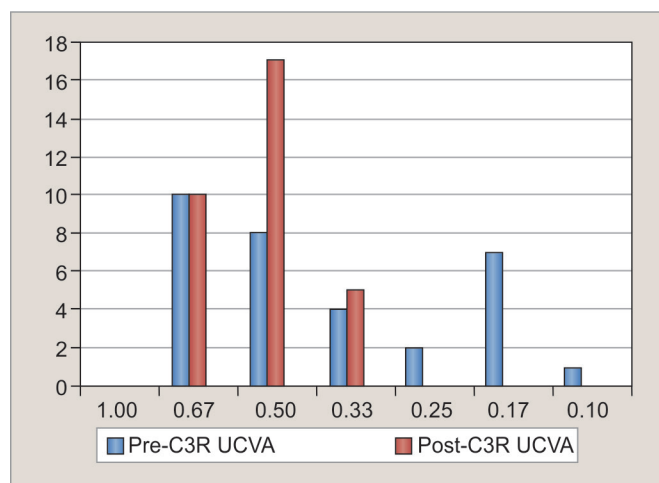
Progression based on Orbscan is considered when ratio between ABFS and PBFS is more than 1.27, posterior dioptric power more than 55, irregular astigmatism is more than 1.5 D in 3-mm zone and 2.5 in 5-mm zone, the keratometric map has a bent bow tie or irregular butterfly pattern, and patients with documented progression of values were selected for the C3R procedure. Subsequent examinations were done at 1, 3, 6 months, and annually. At each examination, refraction, BCVA (Snellen vision charts) with glasses or with contact lenses, corneal topography (Orbscan II Bausch and Lomb), central corneal thickness (CCT) with SP-3000 P Specular microscope (Topcon), and intraocular pressure (Goldmann applanation tonometer, Haag Streit) were recorded. All patients provided informed consent after receiving a detailed description of the nature of the treatment.

## Cross-linking Procedure

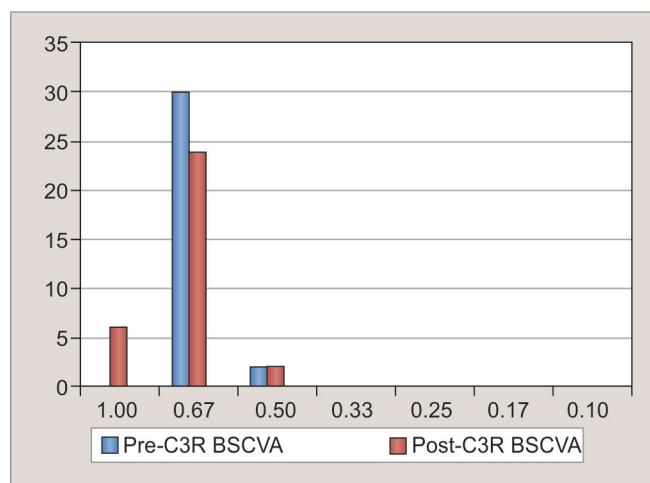
All patients underwent cross-linking procedure on a day surgery basis under strict aseptic conditions. A self-retaining wire speculum was applied to keep the eye open for the procedure. After topical anesthesia of proparacaine hydrochloride 0.5%, the epithelium was removed using a spear sponge in a 9.0-mm diameter area. This was to ensure that the riboflavin penetrated the stroma and a high level of UVA absorption was achieved. As a photosensitizer, 0.1% riboflavin solution was applied to the cornea every 5 minutes for 30 minutes before the irradiation to allow sufficient saturation of the stroma.<sup>14</sup>

Then cornea is exposed to a UV source emanating from a solid-state device system, which emits light at a wavelength of 3 mW/cm<sup>2</sup> or 5.4 J/cm<sup>2</sup>. Exposure lasts for 30 minutes, during which time riboflavin solution is again applied once every 5 minutes. Fixation is achieved by instructing the patient to focus on the central light emitting diode of the probe.

During the procedure, the surgeon has to control the centration. Topical anesthetics were added as needed during irradiation. After the treatment, a bandage contact lens was applied for 1-week duration. Patients were kept on a steroid antibiotic eye drops and tear substitutes topically for 4 weeks. All drops were recommended for use at four times daily. The patients were reviewed subjectively and objectively for refraction, corneal topography with Orbscan on every visit. Follow-up examinations were performed on days 1 and 7 or until complete re-epithelialization.



Graph 1: Pre- and post-C3R UCVA



Graph 2: Pre- and post-C3R BSCVA

Subsequent examinations were done at 1, 3, 6 months and then annually. At each examination, refraction, BCVA (Snellen Vision Charts) with glasses or with contact lenses were recorded, corneal topography (Orbscan II Bausch and Lomb) was done, and CCT was measured with SP-3000 P Specular microscope (Topcon).

To quantify the cross-linking effect, the 3.0-mm and 5.0-mm zone topography, astigmatism, UCVA, and BCVA were recorded.

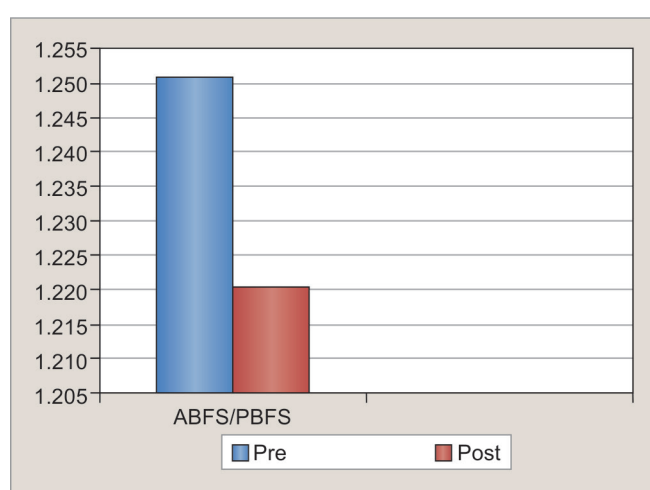
Only patients with a minimum follow-up of 6 months were included in the study. Thirty-two eyes of 21 patients with a mean age of 19.8 years (16–30 years) were included. The follow-up ranged from 6 to 12 months.

The findings were tabulated and relevant statistical analytical tests were applied in consultation with a statistician.

An evaluation of 32 eyes in which stable parameters were recorded and the pre-operative values on the day of treatment were compared with postoperative values of the 6-month examination showed that in our study, males were more commonly affected than the females. Totally, 19 patients were males and 2 females. The youngest patient was 17 years and the oldest was 29 years. The mean age was 19.8 years (16–30 years). There was significant male: female ratio in the study group. About 90.5% of study group cases were males and 9.5% females. In 10 patients, C3R was done in one eye and in 11 patients in both the eyes.

The pre-C3R UCVA were 6/9 in 10 eyes (31.5%), 6/12 in 8 eyes (25%), 6/18 in 4 eyes (12.5%), 6/24 in 2 eyes (6.25%), 6/36 in 7 eyes (21.87%), and 6/60 in 1 eye (3.1%). The post-C3R UCVA changed to 6/9 in 10 eyes (31.5%), 6/12 (0.5) in 17 eyes (53.12%), 6/24 (0.25) in 5 eyes (15.6%) after 6 months of C3R. Hence, the UCVA remained unchanged in 20 (62.5%) eyes and improved by one or two lines in 12 (37.5%) (Graph 1).

The pre-C3R BSCVA was 6/9 (0.67) in 30 eyes (93.75%) and 6/12 (0.5) in 02 eyes (6.25%) (p-value = 0.02). The



Graph 3: Ratio of ABFS/PBFS pre- and post-C3R

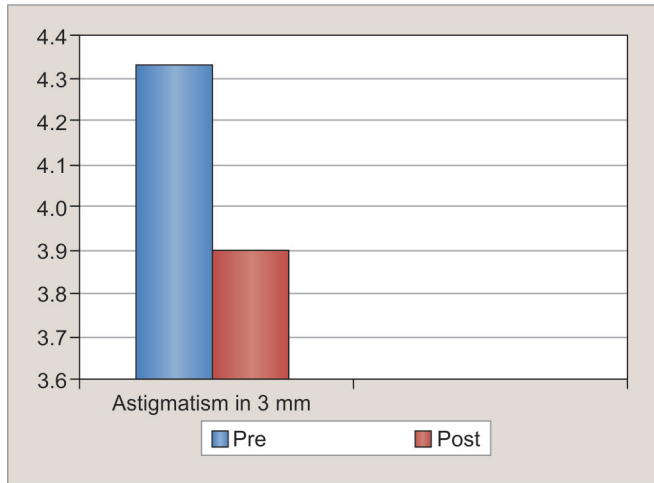
post-C3R BSCVA changed to 6/6 (1.0) in 6 eyes (18.75%), 6/9 (0.67) in 24 eyes (75%), and 6/12 (0.50) in 2 eyes (6.25%) after 6 months. So, the BSCVA increased by one line in 6 eyes (18.75%), and remained stable to preprocedure in 26 eyes (81.25%) (p-value = 0.01; Graph 2).

Student's paired t-test mean value pre-C3R for radii of ABFS/PBFS was  $1.25 \pm 3.7$  and post-C3R after 6 months was  $1.22 \pm 1.8$ . The p-value was statistically significant (0.00;  $p < 0.05$ ; Graph 3).

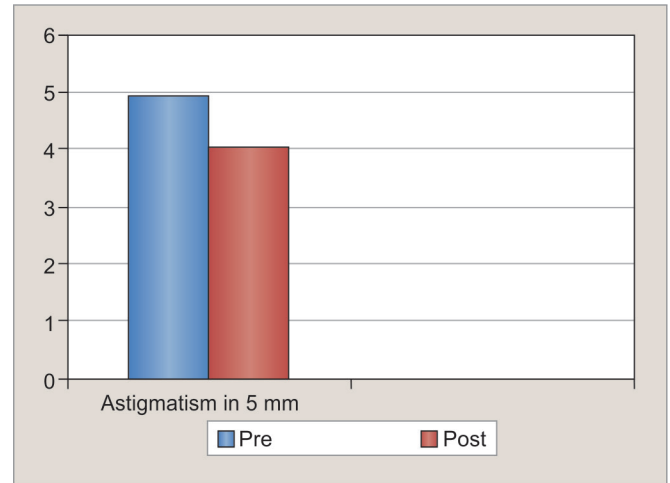
Mean value pre-C3R for astigmatism in 3-mm zone was  $-4.3 \pm 0.98$  and post-C3R value after 6 months was  $-3.9 \pm 0.66$ . The p-value was statistically significant (0.046;  $p < 0.05$ ) in 3-mm zone (Graph 4).

Mean value pre-C3R for astigmatism in 5-mm zone was  $-4.9 \pm 1.91$  and post-C3R value after 6 months was  $-4.0 \pm 0.82$ . The p-value was statistically significant (0.02;  $p < 0.05$ ; Graph 5).

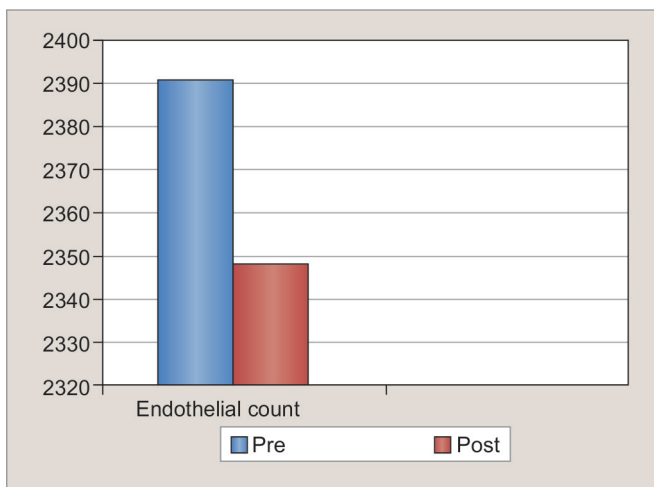
Student's paired t-test mean value pre-C3R for endothelial count was  $2391.09 \pm 82.34$  and post-C3R after 6 months was  $2348.31 \pm 82$ . The p-value was not statistically significant (0.058;  $p > 0.05$ ; Graph 6).



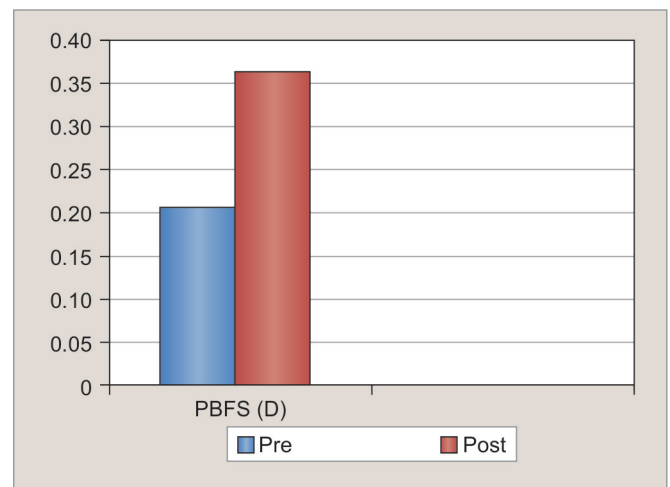
Graph 4: Pre- and post-C3R astigmatism



Graph 5: Pre- and post C3R Astigmatism in 5 mm zone



Graph 6: Pre- and post C3R Endothelial Count



Graph 7: Pre- and post C3R PBFS (D)

Student's paired t-test mean value pre-C3R for PBFS was  $56.66 \pm 1.18$  and post-C3R after 6 months was  $56.74 \pm 1.73$ . The p-value was not statistically significant ( $-0.08$ ;  $p > 0.05$ ; Graph 7).

## DISCUSSION

The results were compiled and analyzed at the end of 1 year of study. We performed C3R procedure in 32 eyes having documented progressive keratoconus of at least 6 months.

Patients willingly opted for refractive surgery in expectation of stopping the progression of keratoconus after surgery. Collagen cross-linking is an approach targeting stromal imbalances due to keratoconus. By using UV irradiation and a photomediator, new covalent cross-links are induced between collagen fibrils, and corneal rigidity improved.<sup>15</sup>

Studies have shown that keratoconus is an uncommon phenomenon among diabetic patients. This possibly reflects collagen cross-linking induced by

advanced glycation endproducts.<sup>16</sup> or following age-related cross-linking of keratoconus by "freezing" the cornea.<sup>17,18</sup>

In our study, the mean age was 19.8 years (16–30 years). There was significant male:female ratio in the study group; 90.5% of study group cases were males and 9.5% females.

In another study done in Indian eyes, 37 eyes with a follow-up of at least 12 months were analyzed, where mean age was  $16.9 \pm 3.5$  years (12–39 years). The mean age was more, 19.8 years (16–30 years) in our study because of selection criteria of age more than 16 years compared with the study where minimum age was 12 years.

The pre-C3R UCVA were 6/9 in 10 eyes (31.5%), 6/12 in 8 eyes (25%), 6/18 in 4 eyes (12.5%), 6/24 in 2 eyes (6.25%), 6/36 in 7 eyes (21.87%), and 6/60 in 1 eye (3.1%).

The post-C3R UCVA changed to 6/9 in 10 eyes (31.5%), 6/12 (0.5) in 17 eyes (53.12%), 6/24 (0.25) in 05 eyes (15.6%) after 6 months of C3R. Thus, the UCVA remained unchanged in 20 (62.5%) eyes and improved by one or two lines in 12 (37.5%).



The pre-C3R BSCVA was 6/9 (0.67) in 30 eyes (93.75%) and 6/12 (0.5) in 2 eyes (6.25%). The post-C3R BSCVA changed to 6/6 (1.0) in 6 eyes (18.75%), 6/9 (0.67) in 24 eyes (75%), and 6/12 (0.50) in 2 eyes (6.25%) after 6 months. So, the BSCVA increased by one line in 6 eyes (18.75%), and remained stable to preprocedure in 26 eyes (81.25%).

Caporossi et al<sup>18</sup> reported a 3.6-line increase in UCVA, a 1.66 line improvement in BSCVA, at 3 months after cross-linking in a series of 10 eyes in 10 patients with progressive keratoconus.

In a prospective study, Wollensak et al performed collagen cross-linking on 22 moderate-to-severe keratoconus patients. Follow-up was for up to 4 years (3–47 months) and included visual acuity, corneal topography, and endothelial cell counts.

This work was the first to show a significant improvement in the outcome of moderate and severe keratoconus patients following collagen cross-linking treatment. In a second study, 10 patients were followed for 6 months after the procedure. In these cases, BCVA improved by an average of 1.66 lines. As in the former study, no changes were noted in endothelial cell counts or intraocular pressure by Caporossi et al.<sup>18</sup>

Raiskup-Wolf et al<sup>19</sup> reported on a larger cohort of patients that the improvement in vision after cross-linking is caused by a decrease in astigmatism and corneal curvature as well as by topographical homogenization of the cornea as a result of the increased rigidity in the cross-linked cornea.

Increase in UCVA and BSCVA concomitant with topographic flattening 6 months after C3R was found. From Graphs 1 and 2, the UCVA and BSCVA data showed mean baseline UCVA was  $0.43 \pm 0.20$  pre-C3R and at 6 months post-C3R was  $0.52 \pm 0.11$ . Pre-C3R mean baseline BSCVA was  $0.65 \pm 3.9$  and after 6 months post-C3R was  $0.71 \pm 0.14$ .

The improvements in means of UCVA with p-value = 0.02 (<0.05) and BSCVA with p-value = 0.01 (<0.05) were statistically significant (<0.05) throughout the entire postoperative period. Both UCVA and BSCVA slowly improved during 6 months after C3R. The results are very similar to other studies. In Indian eyes, in a study, the pre-operative values of BCVA on the day of treatment were compared with postoperative values of the 12-month examination. This showed that BCVA improved at least one line in 54% (67) of eyes and remained stable in 28% (10/37) of eyes (p = 0.006).

**Astigmatism:** The astigmatism in 3- and 5-mm zone showed a significant decrease in cylinder, with p-value of 0.046 and 0.02 respectively. Similar results were seen by Vinciguerra et al.<sup>20</sup> On analysis of total aberrations, they found significant reduction in astigmatism, coma, and spherical aberrations.

**ABFS/PBFS:** The ratio of radii of curvature of ABFS/PBFS on basis of Orbscan reduced significantly after C3R. This could be explained on the basis that collagen cross-linking affects mostly in anterior 300  $\mu\text{m}$  only and flattens it. This depth-dependent stiffening effect may explain significant flattening in anterior cornea and decrease in radii of curvature of anterior best fit sphere and very less effect on posterior cornea, thus reducing the ABFS/PBFS.<sup>20</sup>

This depth-dependent flattening can be explained by a study done on porcine corneas.<sup>21</sup> The stiffening effect was stronger in the anterior-treated flaps than in the posterior-treated flaps and the control flaps (p = 0.001). A 5% strain was achieved at a stress of  $261.7 \pm 133.2 \times 10^3 \text{ N/m}^2$  in the anterior-treated flaps and  $104.1 \pm 52.7 \times 10^3 \text{ N/m}^2$  in the anterior control flaps. The posterior-treated flaps ( $105.0 \pm 55.8 \times 10^3 \text{ N/m}^2$ ) and the posterior control flaps ( $103.7 \pm 61.8 \times 10^3 \text{ N/m}^2$ ) showed no difference (p = 0.95).

**PBFS (D):** The change in power was not statistically significant. The p-value was not statistically significant (-0.08) p > 0.05. The studies in animal experiments have shown that treatment of the cornea with riboflavin and UVA significantly stiffened the cornea only in anterior 300  $\mu\text{m}$ . This depth-dependent stiffening effect may explain significant flattening in anterior cornea and no effect on posterior cornea.<sup>21</sup>

**Endothelial counts:** Endothelial counts were done in the center of cornea with the SP-3000 P Specular microscope (Topcon), and no significant difference in corneal endothelial counts was appreciated when comparing the pre-operative with 6-months measurements. The p-value was not statistically significant (0.058) p > 0.05, indicating that C3R does not result in endothelial loss.

In our study, all subjects had corneal thickness greater than 400  $\mu\text{m}$ . Subjects with corneal pachymetry less than 400  $\mu\text{m}$  were excluded based on Wollensak et al's report that a standard surface UVA dose of 3 mW/cm has a toxic effect on endothelial cells of corneas thinner than 400  $\mu\text{m}$ .

## CONCLUSION

In conclusion, cross-linking seems to be effective in significant UCVA and BSCVA improvement during the first 6 months with no significant change in corneal endothelial cell counts after 12-months measurements of procedure. The lack of evidence for endothelial cell loss is an important safety consideration in assessing this procedure. The results show a stabilization and improvement in keratoconus after collagen cross-linking in Indian eyes suggesting it as an effective treatment for progressive keratoconus. The results are promising and suggest that it would be worthwhile to further investigate application of this procedure and a long follow-up is advisable.

## REFERENCES

1. Tuori AJ, Virtanen I, Aine E, Kalluri R, Miner JH, Uusitalo HM. The immuno histochemical composition of corneal basement membrane in keratoconus. *Curr Eye Res* 1997 Aug;16(8): 792-801.
2. Cheng EL, Maruyama I, SundarRaj N, Sugar J, Feder RS, Yue BY. Expression of type XII collagen and hemidesmosomes-associated proteins in keratoconus corneas. *Curr Eye Res* 2001 May;22(5):333-340.
3. Andreassen TT, Simonsen AH, Oxlund H. Biochemical properties of keratoconus corneas. *Exp Eye Res* 1980 Oct;31(4): 435-441.
4. Rabinowitz YS. Keratoconus. *Surv Ophthalmol* 1998 Jan-Feb;42(4):297-319.
5. Pflugfelder SC, Liu Z, Feuer W, Verm A. Corneal thickness indices discriminate between keratoconus and contact lens induced corneal thickening. *Ophthalmology* 2002 Dec;109(12): 2336-2241.
6. Zadnik K. The ocular examination: measurements and findings. Philadelphia: W.B. Saunders; 1997.
7. Barr JT, Wilson BS, Gordon MO, Rah J, Riley C, Kollbaum PS, Zadnik K; CLEK Study Group. Estimation of the incidence and factors predictive of corneal scarring in the Collaborative Longitudinal Evaluation of Keratoconus (CLEK) Study. *Cornea* 2006 Jan;25(1):16-25.
8. Spoerl E, Wollensak G, Seiler T. Increased resistance of crosslinked cornea against enzymatic digestion. *Curr Eye Res* 2004 Jul;29(1):35-40.
9. Lema I, Durán JA, Ruiz C, Díez-Feijoo E, Acera A, Merayo J. Inflammatory response to contact lenses in patients with keratoconus compared with myopic subjects. *Cornea* 2008 Aug;27(7):758-763.
10. Spoerl E, Mrochen M, Sliney D, Trokel S, Seiler T. Safety of UVA - riboflavin cross-linking of the cornea. *Cornea* 2007 May;26(4):385-389.
11. Seiler T, Huhle S, Spoerl E, Kunath H. Manifest diabetes and keratoconus: a retrospective case-control study. *Graefes Arch Clin Exp Ophthalmol* 2000 Oct;238(10):822-825.
12. Wollensak G, Spoerl E, Seiler T. Riboflavin /ultraviolet-a-induced C3R for the treatment of keratoconus. *Am J Ophthalmol* 2003 May;135(5):620-627.
13. Wollensak G, Spoerl E, Seiler T. Stress-strain measurements of human and porcine corneas after riboflavin-ultraviolet-A-induced cross-linking. *J Cataract Refract Surg* 2003 Sep;29(9): 1780-1785.
14. Vinciguerra P, Epstein D, Albe E, Spada F, Incarnato N, Orzalesi N, Rosetta P. Corneal topography guided penetrating keratoplasty and suture adjustment: new approach for astigmatism control. *Cornea* 2007 Jul;26(6):675-682.
15. Wollensak G. Cross linking treatment of progressive keratoconus: new hope. *Curr Opin Ophthalmol* 2006 Aug;17(4): 356-360.
16. Krueger RR, Ramos-Esteban JC. How might corneal elasticity help us understand diabetes and intraocular pressure? *J Refract Surg* 2007 Jan; 23(1):85-88.
17. Reiser KM. Nonenzymatic glycation of collagen in aging and diabetes. *Proc Soc Exp Biol Med* 1991 Jan;196(1):17-29.
18. Caporossi A, Baiocchi S, Mazzotta C, Traversi C, Caporossi T. Parasurgical therapy for keratoconus by riboflavin-ultraviolet type A rays induced cross-linking of corneal collagen: preliminary refractive results in an Italian study. *J Cataract Refract Surg* 2006 May;32(5):837-845.
19. Raiskup-Wolf F, Hoyer A, Spoerl E, Pillunat LE. Collagen cross-linking with riboflavin and ultraviolet-A light in keratoconus: long-term results. *J Cataract Refract Surg* 2008 May;34(5): 796-801.
20. Vinciguerra P, Albe E, Trazza S, Rosetta P, Vinciguerra R, Seilert T, Epstein D. Refractive, topographic, tomographic, and aberrometric analysis of keratoconic eyes undergoing corneal cross-linking. *Ophthalmology* 2009 Mar;116(3): 369-378.
21. Kohlhaas M, Spoerl E, Schilde T, Unger G, Wittig C, Pillunat LE. Biomechanical evidence of the distribution of cross-links in corneas treated with riboflavin and ultraviolet A light. *J Cataract Refract Surg* 2006;32(2):279-283.