

Intrastromal Corneal Ring Segments in Children with Keratoconus

¹Guilherme Ferrara, ²Paulo Ferrara, ³Leonardo Torquetti

ABSTRACT

Purpose: To evaluate the long-term follow-up of Ferrara intrastromal corneal ring segments (ICRSs) (Ferrara Ophthalmics, Belo Horizonte, Brazil) implantation for the management of keratoconus in children.

Study design: Paulo Ferrara Eye Clinic, Belo Horizonte, Minas Gerais, Brazil.

Materials and methods: A total of 58 eyes of 37 children with keratoconus were included. One or two ring segments were inserted into the cornea, embracing the keratoconus area. Statistical analysis included preoperative and postoperative uncorrected distance visual acuity (UDVA), corrected distance visual acuity (CDVA), asphericity, pachymetry, and keratometry.

Results: Ferrara ICRS implantation significantly improved the mean UDVA and CDVA. Corneal tomography (Pentacam[®]) showed corneal flattening in all eyes implanted with the Ferrara ring. The mean K decreased, and the corneal asphericity and pachymetry increased in all cases.

Conclusion: The Ferrara ICRS improved all parameters after 2 years of implantation in children with keratoconus. There was significant corneal flattening after ring implantation with improvement of the UDVA and the CDVA. All studied parameters remained stable over time.

Keywords: Children, Ferrara ring, Intrastromal corneal ring segments, Keratoconus.

How to cite this article: Ferrara G, Ferrara P, Torquetti L. Intrastromal Corneal Ring Segments in Children with Keratoconus. *Int J Kerat Ect Cor Dis* 2017;6(2):45-48.

Source of support: Nil

Conflict of interest: None

INTRODUCTION

Keratoconus is a corneal ectatic disease characterized by noninflammatory progressive thinning of unknown cause in which the cornea assumes a conical shape.

Intrastromal corneal ring segments have been used to correct ectatic corneal diseases in order to reduce the corneal steepening, reduce the irregular astigmatism, and

improve the visual acuity (VA).¹⁻⁷ Besides, the segments may be a surgical alternative to at least delay, if not eliminate, the need of lamellar or penetrating keratoplasty.

The Ferrara ICRSs are made of PMMA Perspex CQ acrylic. They vary in thickness, and are available in 0.15, 0.20, 0.25, 0.30, and 0.35 mm. The segment cross-section is triangular, and the base for every thickness and diameter is 0.60 mm. The segments have 90°, 120°, 160°, or 210° of arc.

Many studies have demonstrated the efficacy of intrastromal rings to treat many corneal conditions, such as keratoconus,¹⁻⁷ postlaser-assisted *in situ* keratomileusis corneal ectasia,⁸ postradial keratotomy ectasia,⁹ astigmatism,¹⁰ and myopia.¹¹⁻¹⁴ The changes in corneal structure induced by additive technologies can be roughly predicted by Barraquer's thickness law, i.e., when material is added to the periphery of the cornea or an equal amount of material is removed from the central area, a flattening effect is achieved. The corrective result varies in direct proportion to the thickness of the implant and in inverse proportion to its diameter. The thicker and smaller the diameter of the device, the higher the corrective result.¹⁵

In order to investigate the long-term VA and mechanical stability after Ferrara ICRS implantation in children with keratoconus, we conducted the current retrospective study.

MATERIALS AND METHODS

We retrospectively reviewed patient records of 58 eyes of 37 children with keratoconus, which were followed for a period of at least 6 months. The main indication for ICRS implantation was contact lens intolerance and/or progression of the ectasia. The progression of the disease was defined by worsening of UDVA, CDVA (loss of at least 1 line of VA), progressive intolerance to contact lens wear, and progressive corneal steepening documented by corneal topography. Patients were excluded if any of the following criteria applied after preoperative examination: Advanced keratoconus with significant apical opacity and scarring, hydrops, thin corneas, with thickness below 300 μm in the ring track, intense atopia, and any ongoing infectious process, local or systemic.

Patients were separated into two groups, initial and advanced, according to Amsler-Krumeich classification.

Statistical analysis included preoperative and postoperative UDVA, CDVA, keratometry, pachymetry at the

¹⁻³Private Practitioner

^{1,2}Paulo Ferrara Eye Clinic, Belo Horizonte, Minas Gerais, Brazil

³Centro de Excelência em Oftalmologia, Pará de Minas, Brazil

Corresponding Author: Guilherme Ferrara, Av. Contorno, 4747 – Suite 601, Belo Horizonte 30110921, Minas Gerais, Brazil

thinnest point of the cornea, and corneal asphericity. The anterior segment parameters were obtained from Pentacam (Oculus Pentacam®, Germany). Statistical analysis was carried out using the MINITAB software (version 3.3.1). Student's t-test for paired data was used to compare preoperative and postoperative data.

All surgeries were performed by the same surgeon (P.F.) using the manual technique for ICRS implantation, as previously described.¹⁻⁵ The segments were implanted according to a previously described Ferrara nomogram.^{16,17}

After surgery Ketorolac drops were used every 15 minutes for 3 hours, and a combination of 0.1% dexamethasone and 0.3% moxifloxacin or ciprofloxacin drops was used every 4 hours for 7 days, as well as hypromellose (Alcon) every 6 hours for 30 days.

RESULTS

Fifty-eight eyes of 37 patients were studied. Thirteen eyes remained untreated and three eyes underwent lamellar keratoplasty due to advanced keratoconus. The mean age of patients was 13 ± 2.1 years (8–16 years). All patients completed at least 6 months of follow-up (average 20 months, 6–81). No preoperative or postoperative complications occurred.

Preoperative and postoperative UDVA, CDVA, asphericity, pachymetry, and keratometry data were collected from all patients. The mean UDVA at the preoperative period was 0.41 LogMAR, and the mean CDVA was 0.36 LogMAR. At the first month, the mean UDVA improved to 0.29 LogMAR and the mean CDVA improved to 0.20 LogMAR. At the first year follow-up, the mean UDVA was 0.30 LogMAR postoperatively. The mean CDVA, at the first year follow-up, improved to 0.15 LogMAR, at the second year follow-up, the mean UDVA increased slightly to 0.25 LogMAR, and the mean CDVA decreased slightly to 0.16 LogMAR postoperatively (Table 1).

Table 1: UDVA and CDVA variation

	Pre- and postoperative data				
	Preoperative	Postoperative			
		1st month	p-value	2nd year	p-value
UDVA	0.41	0.29	0.004	0.25	0.262
CDVA	0.36	0.2		0.16	0.983

Corneal topography showed corneal flattening in all eyes. The mean K_{minimum} and the mean K_{maximum} decreased in all groups and there was an increase of corneal asphericity and pachymetry. One patient needed cross-linking and one patient needed a lamellar keratoplasty due to progressive steepening despite ICRS implantation.

Minimum Keratometry

Evaluating the results obtained between preoperative and the first month postoperatively, the minimum keratometry reduced, on average, four units (3–5), with 95% confidence interval (CI).

Between the first month and the second year of follow-up, there was no change in minimum keratometry values (p-value = 0.412; Graph 1).

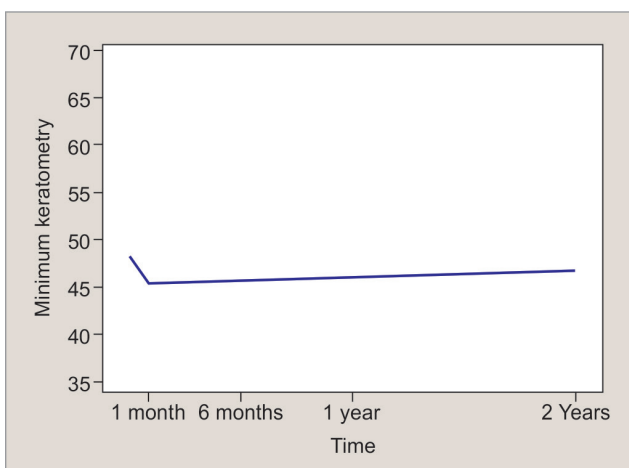
Maximum Keratometry

From the preoperative to the evaluation in the first month, the maximum keratometry decreased, on average, 6 units (4.7–7.3), with 95% CI.

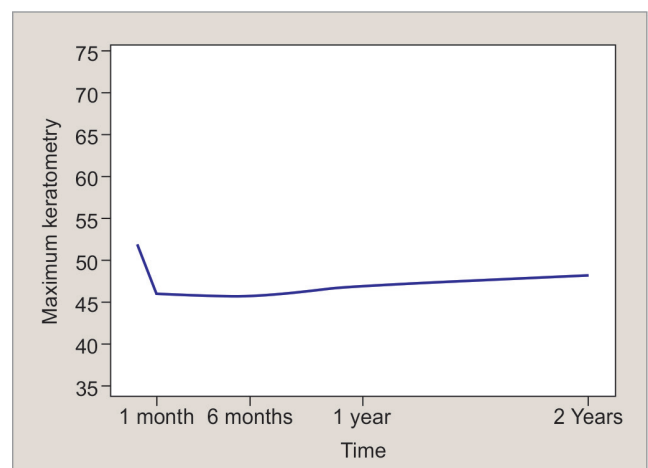
From the first month and the second year of follow-up, the maximum keratometry increased (p-value = 0.002). At each year evaluated, the maximum keratometry increased, on average, 0.7 units (95% CI: 0.2–0.5; Graph 2).

Asphericity

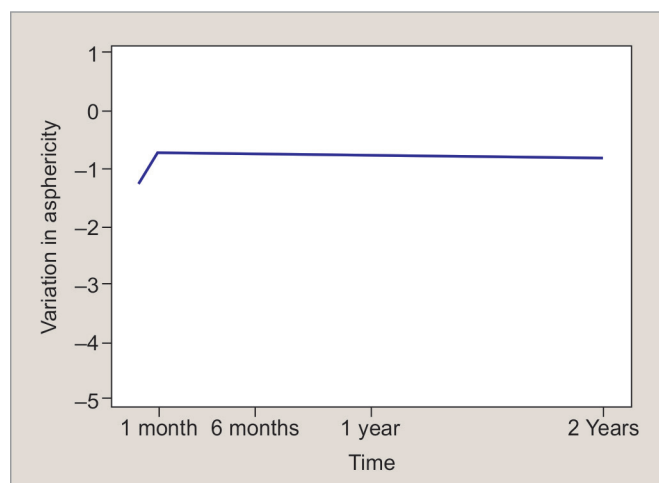
From the preoperative to the first month postoperative, there was an increase in asphericity, which was, on average, 0.61 units (p-value < 0.001).



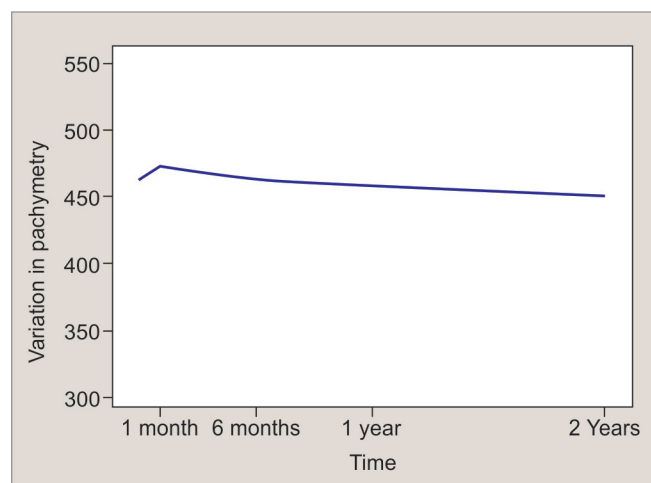
Graph 1: Variation in minimum keratometry over time



Graph 2: Variation in maximum keratometry over time



Graph 3: Variation in asphericity over time



Graph 4: Variation in pachymetry over time

From the first month and the second year of follow-up, the asphericity values remained stable over time (p -value = 0.275; Graph 3).

Corneal Thickness Variation

From the preoperative evaluation to the first month post-operative, there was corneal thickening of, on average, 8.5 units (p -value = 0.05).

From the first month to the second year of follow-up, the corneal thickness remained stable over time (p -value = 0.112; Graph 4).

DISCUSSION

Preliminary investigations have demonstrated that intracorneal rings are effective in the treatment of astigmatism and myopia with astigmatism,¹⁵ with preservation of CDVA and stable results over time.^{16,17} The objective of the additive technology is to reinforce the cornea, decrease the corneal irregularity, and to improve the VA in affected patients.

This is the first study to show the long-term follow-up of children with keratoconus in which the Ferrara ICRS was implanted for at least 6 months. This study is in agreement with some other studies: Miranda et al¹⁸ obtained in their study a significant reduction in the mean central corneal curvature postoperatively. The results showed CDVA and UDVA improved in 87.1 and 80.6% of the eyes respectively. Siganos et al⁴ showed an increase of the mean UDVA from 0.07 ± 0.08 preoperatively to 0.20 ± 0.13 and 0.30 ± 0.21 after 1 and 6 months respectively, and the mean CDVA improved from 0.37 ± 0.25 preoperatively to 0.50 ± 0.43 and 0.60 ± 0.17 after 1 and 6 months respectively. Kwitko and Severo¹⁹ reported that, after implantation of Ferrara ring in keratoconus eye, the CDVA improved in 86.4% of eyes, was unchanged in 1.9%, and worsened in 11.7%. The UDVA improved

in 86.4% of eyes, was unchanged in 7.8%, and worsened in 5.8%. The mean corneal curvature was reduced from 48.76 ± 3.97 to 43.17 ± 4.79 .

The minimum and maximum keratometry decreased from the presurgical evaluation to the first month, while the values of asphericity and pachymetry increased during the same period. Between the first month of follow-up to the second year, we observed that minimum keratometry did not change over time, and maximum keratometry had a slight increase over time. The value of asphericity does not change over time; the pachymetry did not change over time. Although there was a slight increase in maximum keratometry over time (0.7 diopters per year, on average), this increase was not clinically significant.

Based on our personal (unpublished) data, about 5% of patients go to penetrating or lamellar keratoplasty due to progressive corneal scarring, despite proper ICRS implantation. It is important to emphasize that these patients usually had ring implantation in very advanced phases of the disease and does not mean necessarily keratoconus evolution but rather an unsatisfactory visual outcome. In our study, two patients (5.4%) underwent keratoplasty and one patient (2.7%) underwent corneal crosslinking due to keratoconus progression.

Alió et al²⁰ conducted a retrospective study to evaluate the long-term (up to 48 months) results after implantation of Intacs in patients with keratoconus. They found that the mean CDVA increased significantly ($p < 0.01$) from 0.46 (20/50) preoperatively to 0.66 (20/30) 6 months after implantation. Also, the mean average K-value decreased significantly ($p < 0.01$) by 3.13D. The comparison of results 6 months and 36 months after implantation showed refraction and topography stability.

Kymionis et al²¹ studied 17 eyes of patients with keratoconus that had Intacs implantation for corneal flattening. They found that the pre-Intacs UDVA was 20/50 or

worse in all eyes, whereas, at the last follow-up examination, 59% had UDVA of 20/50 or better. Most of the eyes (59%) experienced a gain of one up to eight lines of VA.

Previous studies showed that the intrastromal ring flattens the cornea and keeps this effect for a long period of time. There is no significant resteeptening of the cornea over time in adults. We found that the preoperative keratometry values were higher in our study when compared with similar studies.²⁰⁻²² Moreover, the preoperative UDVA and CDVA were worse in our study. This can be explained by the behavior of keratoconus in some children, which can rapidly evolve, and when the surgery is indicated the disease is more advanced.

There was improvement of all parameters in our study. The pattern of reduction of keratometry parameters was similar to other studies. Despite that, at 5 years of follow-up we found corneal resteeptening on maximum keratometry, which was not found in other studies when compared with our results. Regarding the VA, there was improvement in UDVA and CDVA, but not as much as in adults.

The present study showed that the Ferrara ring, despite the small sample of patients, could be a valuable tool to provide topographic and visual improvement in children with keratoconus. Corneal re-steepening can occur after ICRS implantation. It plays an important role in delaying the progression of keratoconus and postpones a corneal grafting surgery. Further studies with larger samples and longer follow-up periods must be warranted to confirm the presented results.

REFERENCES

- Colin J, Velou S. Implantation of Intacs and a refractive intra-ocular lens to correct keratoconus. *J Cataract Refract Surg* 2003 Apr;29(4):832-834.
- Asbell PA, Uçakhan OO. Long-term follow-up of Intacs from a single center. *J Cataract Refract Surg* 2001 Sep;27(9):1456-1468.
- Colin J, Cochener B, Savary G, Malet F. Correcting keratoconus with intracorneal rings. *J Cataract Refract Surg* 2000 Aug;26(8):1117-1122.
- Siganos D, Ferrara P, Chatzinikolas K, Bessis N, Papastergiou G. Ferrara intrastromal corneal rings for the correction of keratoconus. *J Cataract Refract Surg* 2002 Nov;28(11):1947-1951.
- Colin J, Cochener B, Savary G, Malet F, Holmes-Higgin D. INTACS inserts for treating keratoconus; one-year results. *Ophthalmology* 2001 Aug;108(8):1409-1414.
- Siganos CS, Kymionis GD, Kartakis N, Theodorakis MA, Astyrakakis N, Pallikaris IG. Management of keratoconus with Intacs. *Am J Ophthalmol* 2003 Jan;135(1):64-70.
- Assil KK, Barrett AM, Fouraker BD, Schanzlin DJ. One-year results of the intrastromal corneal ring in nonfunctional human eyes. *Intrastromal Corneal Ring Study Group. Arch Ophthalmol* 1995 Feb;113(2):159-167.
- Siganos CS, Kymionis GD, Astyrakakis N, Pallikaris IG. Management of corneal ectasia after laser *in situ* keratomileusis with INTACS. *J Refract Surg* 2002 Jan-Feb;18(1):43-46.
- Silva FBD, Alves EAF, Cunha PFA. Utilização do Anel de Ferrara na estabilização e correção da ectasia corneana pós PRK. *Arq Bras Oftalmol* 2000 Jun;63(3):215-218.
- Ruckhofer J, Stoiber J, Twa MD, Grabner G. Correction of astigmatism with short arc-length intrastromal corneal ring segments: preliminary results. *Ophthalmology* 2003 Mar;110(3):516-524.
- Nosé W, Neves RA, Burris TE, Schanzlin DJ, Belfort Júnior R. Intrastromal corneal ring: 12-month sighted myopic eyes. *J Refract Surg* 1996 Jan;12(1):20-28.
- Schanzlin DJ, Asbell PA, Burris TE, Durrie DS. The intrastromal ring segments. Phase II results for the correction of myopia. *Ophthalmology* 1997 Jul;104(7):1067-1078.
- Holmes-Higgin DK, Burris TE, Lapidus JA, Greenlick MR. Risk factors for self-reported visual symptoms with Intacs inserts for myopia. *Ophthalmology* 2002 Jan;109(1):46-56.
- Asbell PA, Uçakhan OO, Abbott RL, Assil KA, Burris TE, Durrie DS, Lindstrom RL, Schanzlin DJ, Verity SM, Waring GO 3rd. Intrastromal corneal ring segments: reversibility of refractive effect. *J Refract Surg* 2001 Jan-Feb;17(1):25-31.
- Barraquer JI. Modification of refraction by means of intracorneal inclusions. *Int Ophthalmol Clin* 1966 Spring;6(1):53-78.
- Ferrara de A, Cunha P. Técnica cirúrgica para correção de miopia. Anel corneano intra-estromal. *Rev Bras Oftalmol* 1995;54(8):577-588.
- Bock RH, Maumenee AE. Corneal fluid metabolism: experiments and observations. *Arch Ophthalmol* 1953 Sep;50(3):282-285.
- Miranda D, Sartori M, Francesconi C, Allemann N, Ferrara P, Campos M. Ferrara intrastromal corneal ring segments for severe keratoconus. *J Refract Surg* 2003 Nov-Dec;19(6):645-653.
- Kwitko S, Severo N. Ferrara intracorneal ring segments for keratoconus. *J Cataract Refract Surg* 2004 Apr;30(4):812-820.
- Alió JI, Shabayek MH, Artola A. Intracorneal ring segments for keratoconus correction: long-term follow-up. *J Cataract Refract Surg* 2006 Jun;32(6):978-985.
- Kymionis GD, Siganos CS, Tsiklis NS, Anastasakis A, Yoo SH, Pallikaris AI, Astyrakakis N, Pallikaris IG. Long-term follow-up of Intacs in Keratoconus. *Am J Ophthalmol* 2007 Feb;143(2):236-244.
- Colin J, Malet FJ. Intacs for the correction of keratoconus: two-year follow-up. *J Cataract Refract Surg* 2007 Jan;33(1):69-74.