

CASE SERIES

Pathogenesis of Fixed Dilated Pupil (Urrets-Zavalía Syndrome) after Deep Lamellar Keratoplasty in Keratoconus

¹José RC Reis, ²Alberto Diniz-Filho, ³Fábio M Rocha, ⁴Leonardo Torquetti

ABSTRACT

Purpose: To present a case series of patients that developed Urrets-Zavalía syndrome (UZS) after deep anterior lamellar keratoplasty (DALK) for treating keratoconus and discuss the mechanisms for the syndrome.

Materials and methods: Retrospective chart analysis of patients who developed UZS after DALK at the Cornea Unit, Hospital São Geraldo, Federal University of Minas Gerais.

Results: We present a series of 3 patients with features consistent with UZS, after undergoing DALK. Elevated intraocular pressure (IOP) was noted in the early postoperative period in 2 cases, despite the fact that the other case reported eye pain, headache, and nausea at the night after the surgery with undocumented IOP. Although at different extents, the pupil remained atrophic and dilated in all 3 eyes, and 2 of them developed anterior subcapsular cataract.

Conclusion: Iris ischemia resulting from occlusion of iris root vessels due to elevated IOP higher than diastolic blood pressure causes UZS. Elevated IOP should be monitored, especially in young patients with low diastolic blood pressure, in order to avoid the occurrence of the syndrome.

Keywords: Cornea, Keratoconus, Keratoplasty, Pupil.

How to cite this article: Reis JRC, Diniz-Filho A, Rocha FM, Torquetti L. Pathogenesis of Fixed Dilated Pupil (Urrets-Zavalía Syndrome) after Deep Lamellar Keratoplasty in Keratoconus. *Int J Kerat Ect Cor Dis* 2016;5(1):32-34.

Source of support: Nil

Conflict of interest: None

^{1,3}Clinical and Surgical Instructor, ²Clinical Instructor and Researcher, ⁴Head Surgeon

¹Department of Surgery, University Hospital, Federal University of Triângulo Mineiro, Uberaba, Minas Gerais, Brazil

²Department of Ophthalmology and Otorhinolaryngology Glaucoma Unit, Federal University of Minas Gerais, Belo Horizonte, Brazil

³Department of Ophthalmology and Otorhinolaryngology Cornea Unit, Hospital São Geraldo, Federal University of Minas Gerais, Belo Horizonte, Brazil

⁴Department of Ophthalmology, Center for Excellence in Ophthalmology, Pará de Minas, Brazil

Corresponding Author: José RC Reis, Clinical and Surgical Instructor, Department of Surgery, University Hospital Federal University of Triângulo Mineiro, Uberaba, Minas Gerais 38025-180, Brazil, Phone: +553433185000 e-mail: jroftalmo@gmail.com

INTRODUCTION

The occurrence of fixed and dilated pupil after penetrating keratoplasty (PK) was first mentioned by Urrets-Zavalía in 1962,¹ when he published a series of six cases, although he attributes the recognition of the Castroviejo syndrome.

Urrets-Zavalía syndrome (UZS) was initially described as a complication of PK in keratoconus.²⁻⁴ However, UZS can occur after PK for corneal dystrophies and may not be limited to eyes with keratoconus.⁵ It has also been reported following endothelial keratoplasty,^{6,7} trabeculectomy,⁸ argon laser peripheral iridoplasty,⁹ goniotomy,¹⁰ cataract surgery,¹¹ and pupil dilation in eyes with pigment dispersion.¹²

Besides fixed and dilated pupil, the UZS presents other findings, such as iris atrophy, uveal ectropion, pigment dispersion, posterior synechiae, and anterior subcapsular cataract. These findings are very similar to those found in an acute primary angle closure episode.

We report three keratoconus patients who developed fixed dilated pupil after deep anterior lamellar keratoplasty (DALK) using Anwar's technique. The mean follow-up was 14 months (9–18 months).

CASE REPORTS

Case 1

A 13-year-old girl with advanced keratoconus in the right eye underwent DALK using the technique of big-bubble. During the procedure, there was a microperforation of Descemet membrane. An air bubble was placed in the anterior chamber so that the surgery was completed without the need to convert to PK. The air bubble was left in the anterior chamber at the end of surgery, in order to avoid the formation of double anterior chamber, which happens when the aqueous humor enters into the microperforation and separates the Descemet membrane from the donor cornea. On the first day after surgery, the intraocular pressure (IOP) was normal, but the patient reported eye pain, headache, nausea, and malaise at the night after the surgery. On the fifth day after surgery, the air was resorbed; there was a double anterior chamber and a dilated pupil with posterior synechiae. The Descemet membrane and endothelium of the receptor

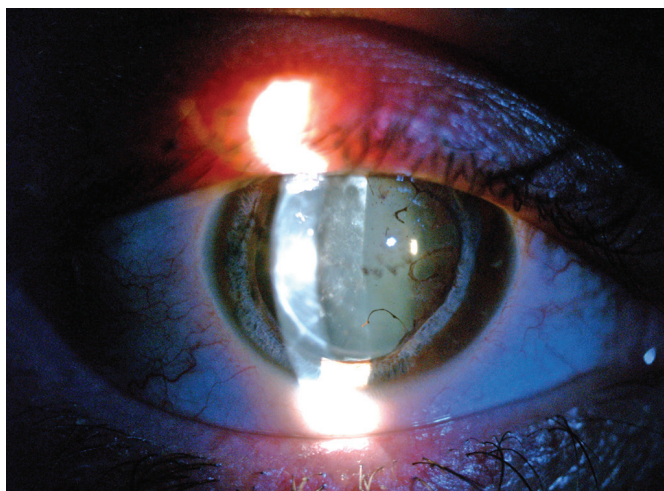


Fig. 1: Anterior subcapsular cataract and fixed mydriasis UZS after DALK

were surgically removed with significant improvement of corneal edema. The pupil remained dilated and atrophic, and there was a formation of an anterior subcapsular cataract.

Case 2

A 25-year-old man with advanced keratoconus in the right eye underwent DALK using the technique of big-bubble with microperforation of Descemet membrane, during the procedure. An air bubble was placed in the anterior chamber, at the end of surgery. On the first day after surgery, the IOP was 18 mm Hg. The patient reported malaise and nausea during the night. On the fifth day after surgery, IOP rose to 40 mm Hg and the pupil was fixed and dilated; there was an intense inflammatory reaction in the anterior chamber with formation of an inflammatory membrane over the pupil. Hypotensive and anti-inflammatory eye drops were administered, with an improvement in IOP and inflammation. Patient developed anterior subcapsular cataract and long-standing mydriasis with reduced reactivity to topical pilocarpine (Fig. 1).

Case 3

A 23-year-old girl with advanced keratoconus in the right eye underwent DALK using the technique of big-bubble with microperforation of Descemet membrane during the procedure. An air bubble was placed and left in the anterior chamber. At surgery, drops of phenylephrine (10%) and tropicamide (1%) were instilled to avoid pupillary block by the air bubble. On the first day after surgery, the IOP was 25 mm Hg. Anti-inflammatory and hypotensive (including oral acetazolamide) eye drops were used for control of IOP and the ocular inflammation. The pupil, though not as dilated as the other two previous cases, showed slight atrophy, and the pupillary reflex was

quite reduced. Furthermore, there were signs of posterior synechiae. The lens remained clear.

DISCUSSION

The DALK procedure brought some advantages over the PK regarding the treatment of corneal diseases that spare the endothelium (e.g., keratoconus). The advantages are absence of endothelial rejection, less endothelial cell loss in the medium and long term, greater resistance to trauma, and greater availability of donor corneas.^{13,14}

The major disadvantage is the technical difficulty of exposing the Descemet membrane, often leading to its perforation.¹⁵ Den et al¹⁶ had 26.0% of microperforation of the Descemet membrane during the surgery, with decreased graft survival in these eyes. In the past, corrected distance visual acuity (CDVA) after PK was usually better than after DALK. However, the big-bubble technique made possible obtaining a good exposure of the Descemet membrane with a minimal amount of residual stroma, what provides a better CDVA compared with other techniques of DALK.¹⁷⁻²⁰

The most accepted mechanism for UZS is the increased IOP as the cause of iris ischemia. Tuft and Buckley²¹ noticed an IOP increase in two of the three patients that had UZS, suggesting that the ocular hypertension associated with low rigidity in eyes with keratoconus would cause closure of blood vessels at the iris root, resulting in iris ischemia. It has been suggested that an elevated IOP on the first day was a significant factor in the development of UZS after PK in keratoconus.

Technical changes in DALK may lead to increased IOP, both intra- and postoperatively. If the paracentesis is not made after introduction of the air bubble, the IOP may rise during dissection of the corneal stroma. In addition, if any accidental perforation of the Descemet's membrane occurs, the air injection into the anterior chamber may lead to a pupillary block and elevation of IOP in the postoperative period.

Minasian and Ayliffe²² published a case series of UZS after DALK, wherein there was occurrence of pain postoperatively. The authors speculated if the cause of UZS could be a pupillary block caused by air or gas in the anterior chamber, followed by IOP rise and iris ischemia. Iris ischemia occurs when the IOP is higher than the diastolic blood pressure, as described in a study using monkey eyes.²³ Another study showed that the iris and ciliary processes are the first tissues to show signs of ischemia due to elevation of IOP.¹³

Keratoconus is a disease mainly diagnosed in young patients, who usually have a low diastolic blood pressure, mainly at nighttime.²⁴ Therefore, it would not be necessary

for a large IOP increase in order to have an episode of iris ischemia in these patients. Previous studies showed that not all patients with keratoconus who developed UZS showed an increase in IOP postoperatively. Moreover, in patients who developed UZS due to other causes (e.g., after endothelial keratoplasty) the increase in IOP was remarkable.^{2,9}

It is important to keep rigorous intraoperative management of ocular viscoelastic devices and aggressive postoperative IOP control in patients undergoing DALK for keratoconus, especially in young patients. In cases of Descemet membrane rupture requiring injection of air into the anterior chamber, the air bubble should be mobile and the pupil should be dilated in order to avoid a pupillary block. Patients should be evaluated few hours after the procedure to detect possible IOP spikes, which should be treated aggressively.

In conclusion, iris ischemia resulting from occlusion of iris root vessels due to elevated IOP higher than diastolic blood pressure causes UZS. The IOP should be monitored, especially in young patients with low diastolic blood pressure, in order to avoid the occurrence of the syndrome.

REFERENCES

1. Urrets-Zavalía A Jr. Fixed, dilated pupil, iris atrophy and secondary glaucoma. *Am J Ophthalmol* 1963 Aug;56: 257-265.
2. Urrets-Zavalía A. Management of keratoplasty in the early stages. *Br J Ophthalmol* 1977 Feb;61(2):89-91.
3. Bertelsen T, Seim V. Irreversible mydriasis following keratoplasty in keratoconus [proceedings]. *Acta Ophthalmol Suppl* 1975;(125):45-46.
4. Saraux H, Offret H, Binaghi M. Urrets-Zavalía syndrome. *Bull Soc Ophtalmol Fr* 1978 Aug-Sep;78(8-9):579-584.
5. Srinivasan M, Patnaik L. Fixed dilated pupil (Urrets-Zavalía syndrome) in corneal dystrophies. *Cornea* 2004 Jan;23(1): 81-83.
6. Fournie P, Ponchel C, Malecaze F, Arne JL. Fixed dilated pupil (Urrets-Zavalía syndrome) and anterior subcapsular cataract formation after Descemet stripping endothelial keratoplasty. *Cornea* 2009 Dec;28(10):1184-1186.
7. Russell HC, Srinivasan S. Urrets-Zavalía syndrome following Descemet's stripping endothelial keratoplasty triple procedure. *Clin Exp Ophthalmol* 2011 Jan;39(1):85-87.
8. Jain R, Assi A, Murdoch IE. Urrets-Zavalía syndrome following trabeculectomy. *Br J Ophthalmol* 2000 Mar;84(3): 338-339.
9. Espana EM, Ioannidis A, Tello C, Liebmann JM, Foster P, Ritch R. Urrets-Zavalía syndrome as a complication of argon laser peripheral iridoplasty. *Br J Ophthalmol* 2007 Apr;91(4):427-429.
10. Chelnis JG, Sieminski SF, Reynolds JD. Urrets-Zavalía syndrome following goniotomy in a child. *J AAPOS* 2012 Jun;16(3):312-313.
11. Tan AK, Humphry RC. The fixed dilated pupil after cataract surgery – is it related to intraocular use of hypromellose? *Br J Ophthalmol* 1993 Oct;77(10):639-641.
12. Mocan MC, Bozkurt B, Irkeç M, Orhan M. Urrets-Zavalía syndrome following iatrogenic pupil dilation in eyes with pigment dispersion. *Can J Ophthalmol* 2009 Apr;44(2):216-217.
13. Anderson DR, Davis EB. Sensitivities of ocular tissues to acute pressure-induced ischemia. *Arch Ophthalmol* 1975 Apr;93(4):267-274.
14. Anwar M, Teichmann KD. Big-bubble technique to bare Descemet's membrane in anterior lamellar keratoplasty. *J Cataract Refract Surg* 2002 Mar;28(3):398-403.
15. Bozkurt KT, Acar BT, Acar S. Fixed dilated pupilla as a common complication of deep anterior lamellar keratoplasty complicated with Descemet membrane perforation. *Eur J Ophthalmol* 2013 Mar-Apr;23(2):164-170.
16. Den S, Kawashima M, Shimmura M, Imai Y, Satake Y, Shimazaki J. How good is transplantation of corneal parts compared with penetrating keratoplasty? *Cornea* 2010 Nov;29 (Suppl 1):S48-S51.
17. Shimazaki J, Shimmura S, Ishioka M, Tsubota K. Randomized clinical trial of deep lamellar keratoplasty vs penetrating keratoplasty. *Am J Ophthalmol* 2002 Aug;134(2):159-165.
18. Watson SL, Ramsay A, Dart JK, Bunce C, Craig E. Comparison of deep lamellar keratoplasty and penetrating keratoplasty in patients with keratoconus. *Ophthalmology* 2004 Sep;111(9): 1676-1682.
19. Terry MA, Ousley PJ. Deep lamellar endothelial keratoplasty visual acuity, astigmatism, and endothelial survival in a large prospective series. *Ophthalmology* 2005 Sep;112(9):1541-1548.
20. Cohen AW, Goins KM, Sutphin JE, Wandling GR, Wagoner MD. Penetrating keratoplasty versus deep anterior lamellar keratoplasty for the treatment of keratoconus. *Int Ophthalmol* 2010 Dec;30(6):675-681.
21. Tuft SJ, Buckley RJ. Iris ischaemia following penetrating keratoplasty for keratoconus (Urrets-Zavalía syndrome). *Cornea* 1995 Nov;14(6):618-622.
22. Minasian M, Ayliffe W. Fixed dilated pupil following deep lamellar keratoplasty (Urrets-Zavalía syndrome). *Br J Ophthalmol* 2002 Jan;86(1):115-116.
23. Charles ST, Hamasaki DI. The effect of intraocular pressure on the pupil size. *Arch Ophthalmol* 1970 Jun;83(6):729-733.
24. Langowski AR, Lima Junior E, Knopffholz J, Reichert A, Nogueira MO, Faria Neto JR, Guarita-Souza LC. Arterial pressure monitoring in offspring of hypertensive individuals at a day-care center. *Rev Assoc Med Bras* 2008 Mar-Apr;54(2):163-166.