

Accuracy of Topometric Indices for Distinguishing between Keratoconic and Normal Corneas

Marcella Q Salomao, Frederico P Guerra, Isaac C Ramos, Livia F Jordao, Ana Laura C Canedo, Bruno F Valbon Allan Luz, Rosane Correa, Bernardo Lopes, Renato Ambrósio Jr

ABSTRACT

Purpose: To evaluate the sensitivity and specificity of the Pentacam topometric indices derived from the corneal surface curvature to distinguish between normal and keratoconic corneas.

Methods: The study consisted of 226 normal corneas from 113 patients and 88 keratoconic eyes from 44 patients. Eyes were defined as keratoconus based on comprehensive ocular examination, including Placido-disk-based corneal topography (Atlas Corneal Topography System; Humphrey, San Leandro, California) and rotating Scheimpflug corneal tomography (Pentacam HR; Oculus, Wetzlar, Germany). Corneal Topometric indices ISV, IVA, KI, CKI, IHA and IHD, along with the TKC (Topometric Keratoconus Classification) score were calculated from the Pentacam HR exam. Statistical analysis were accomplished using BioEstat 5.0 (Instituto Mamiraua, Amazonas, Brazil) and MedCalc 12.0 (MedCalc Software, Mariakerke, Belgium) using unpaired nonparametric Mann Whitney test (Wilcoxon ranked-sum). ROC curves were calculated for each topometric parameter to determine the best cut off values from the significantly different parameters. A logistic regression analysis was performed to provide a combined parameter for optimizing accuracy.

Results: Statistical significant differences were found between keratoconic and normal corneas for all topometric indices (Mann Whitney, $p < 0.05$). There were four false negative cases among the keratoconic cases on the TKC classification (4.54%) and 16 false positive cases among normal (7.08%), so that the sensitivity and specificity of the TKC were 95.54 and 92.92% respectively. The areas under the ROC curves (AUC) for the individual topometric indices varied from 0.843 (CKI) and 0.992 (ISV). The sensitivity and specificity of the most accurate ISV were 97.7 and 96.5% respectively. The calculated parameter from logistic regression had AUC of 0.996, with sensitivity of 97.7% and specificity of 98.7%.

Conclusion: Pentacam topometric indices were useful for distinguishing between normal and keratoconic corneas. The TKC classification should be expected to have false positives and negatives and should not be considered alone. TKC had more false positives and false negatives than some individual topometric parameters. A novel combined parameter based on logistic regression analysis may improve accuracy for the diagnosis of keratoconus. Further studies are necessary to evaluate if adding other curvature derived indices is beneficial for the regression analysis, as well as for testing the sensitivity of such parameters for the diagnosis of milder forms of ectasia and for testing correlations with severity of the disease.

Keywords: Keratoconus, Ectasia, Corneal topography, Corneal tomography.

How to cite this article: Salomao MQ, Guerra FP, Ramos IC, Jordao LF, Canedo ALC, Valbon BF, Luz A, Correa R, Lopes B, Ambrósio Jr R. Accuracy of Topometric Indices for Distinguishing between Keratoconic and Normal Corneas. *J Kerat Ect Cor Dis* 2013;2(3):108-112.

Source of support: Nil

Conflict of interest: None

INTRODUCTION

Keratoconus (KC) is a bilateral, noninflammatory ectatic condition, characterized by progressive stromal thinning and consequent protrusion of the cornea.^{1,2} The incidence of keratoconus tends to be higher among refractive candidates than in general population and this condition is a well-accepted contraindication for laser *in situ* keratomileusis (LASIK).³ A skillful physician can easily identify typical signs of the disease in advanced stages, including Fleischer ring, Vogt striae, Munson sign and Rizzuti sign.^{1,2} However, KC has a wide range of severity and onset, and the identification of subclinical forms of the disease in patients with normal best spectacle-corrected visual acuity and minimal or no clinical signs is still a challenge. Amsler⁴ was the first to describe these milder forms of KC using photokeratoscopy. Later on, Klyce⁵ and Rabinowitz² developed algorithms for surface evaluation using videokeratoscopy, which unquestionably enhanced our sensitivity and specificity to detect such cases.

Nevertheless, there is little agreement as to what constitutes the minimal topographic criteria for making the diagnosis of keratoconus based solely on corneal anterior surface curvature data. Parameters have been developed to improve standardization. Objective computer programs with quantitative indices have also been developed to help clinicians on subjective interpretations based on the data.⁶⁻⁹ One of the most important applications of corneal topography was in the screening of refractive surgery candidates, along with evaluation and improvement of corneal surgical procedures.¹⁰⁻¹⁴

The goal of this study was to evaluate the sensitivity and specificity of the topometric indices generated by the Oculus Pentacam derived from the curvature data of the 8 mm corneal front surface, for discriminating keratoconus from normal corneas.

METHODS

The retrospective study adhered to the tenets of the Declaration of Helsinki. The study was approved by the ethics committee of the Federal University of São Paulo, Brazil. Patients were retrospectively enrolled from the Instituto de Olhos Renato

Ambrósio (Rio de Janeiro, Brazil). All eyes were examined by a fellowship-trained cornea and refractive surgeon (RA). Eighty-eight eyes from 44 patients with clinical keratoconus (KK group) were retrospectively selected and compared to an age-matched control group comprised of 226 normal eyes from 113 patients (NN group). Along with a comprehensive ocular examination, all eyes were examined by Placido-disk-based corneal topography (Atlas Corneal Topography System; Humphrey, San Leandro, California) and rotating Scheimpflug corneal tomography [Pentacam HR (Oculus, Wetzlar, Germany)]. Diagnosis of keratoconus was made based on Placido-disk-based axial topography, elevation-derived anterior corneal curvature maps, and criteria used in the collaborative longitudinal evaluation of keratoconus (CLEK) study.¹⁵ Cases with a history of corneal surgery or with extensive corneal scarring were excluded from the study. Contact lens wearers were asked to discontinue the use at least 3 weeks prior to the examinations.

Special Pentacam software was used to automatically extract the data of each patient exam into a Microsoft Excel spreadsheet. The following corneal front surface topometric indices were calculated from the Pentacam exam and analyzed: index of surface variance (ISV), index of vertical asymmetry (IVA), keratoconus index (KI), center keratoconus index (CKI), index of height asymmetry (IHA) and index of height decentration (IHD), along with the topographical keratoconus classification (TKC) score.

Statistical analysis was accomplished using BioEstat 5.0 (Instituto Mamiraua, Amazonas, Brazil) and MedCalc 12.0

(MedCalc Software, Mariakerke, Belgium) using unpaired nonparametric Mann Whitney test (Wilcoxon ranked-sum) to assess if the parameters have different distributions among the groups. A p-value < 0.05 was considered statistically significant. Receiver operating characteristic (ROC) curves were calculated for each topometric parameter to determine the best cut off values from the significantly different parameters and to determine the test's overall predictive accuracy and area under the curve. A logistic regression analysis was performed to provide a combined parameter for optimizing accuracy in detecting keratoconus among normals.

RESULTS

There were no statistical differences for patient age or gender between the groups. Statistical significant differences were found between keratoconic and normal corneas for all topometric indices (Mann Whitney, $p < 0.001$). Mean, range and standard deviation of topometric parameters are displayed in Table 1.

The areas under the ROC curves (AUC) for the individual topometric indices varied from 0.843 (CKI) and 0.992 (ISV). The most accurate parameter was ISV, with sensitivity and specificity of 97.7 and 96.5% respectively. Table 2 summarizes the ROC data for all topometric parameters studied. Figure 1 illustrates the dot plot distributions of all topometric indices. Figure 2 illustrates the ROC curves for all topometric parameters.

Table 1: Mean range and standard deviation of topometric parameters on normal and KC

	Normal				Keratoconus				p-value
	Mean	Min	Max	SD	Mean	Min	Max	SD	
ISV	22.45	9	77	7.66	93.02	26	199	40.75	<0.001
IVA	0.21	0.06	0.62	0.08	0.89	0.16	1.88	0.37	<0.001
KI	1.02	0.94	1.12	0.03	1.24	0.94	1.68	0.13	<0.001
CKI	1.00	0.97	1.05	0.009	1.05	0.96	1.29	0.06	<0.001
IHA	5.33	0	26.3	4.59	28.75	0.5	88.8	19.01	<0.001
IHD	0.01	0.002	0.22	0.01	0.08	0.01	0.21	0.04	<0.001

Table 2: ROC data for the topometric parameters

	Criterion	Sensitivity (%)	Specificity (%)	AUC	SE ^a	95% CI ^b
ISV	>36	97.7	96.5	0.992	0.00404	0.975 to 0.999
IVA	>0.38	92.0	98.7	0.978	0.0103	0.955 to 0.991
KI	>1.07	96.6	96.5	0.982	0.0121	0.960 to 0.994
CKI	>1.01	73.9	95.6	0.843	0.0321	0.798 to 0.882
IHA	>10	83.0	87.6	0.911	0.0212	0.874 to 0.940
IHD	>0.031	93.2	97.8	0.983	0.00746	0.962 to 0.994
LogRegrTopom1		97.7	98.7	0.996	0.00287	0.981 to 1.000

^aDeLong et al, 1988; ^bBinomial exact

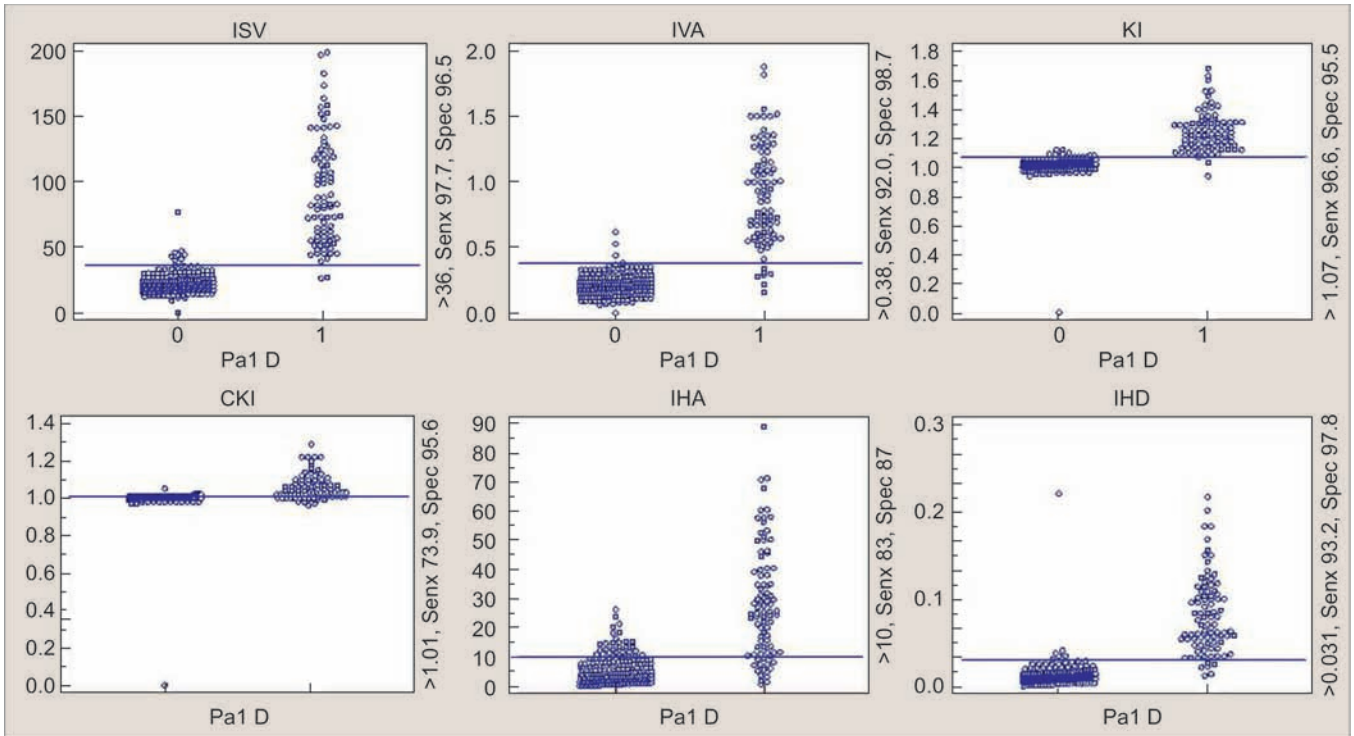


Fig. 1: Dot plots for the topometric parameters — sensitivity, specificity and criterion of each topometric parameter

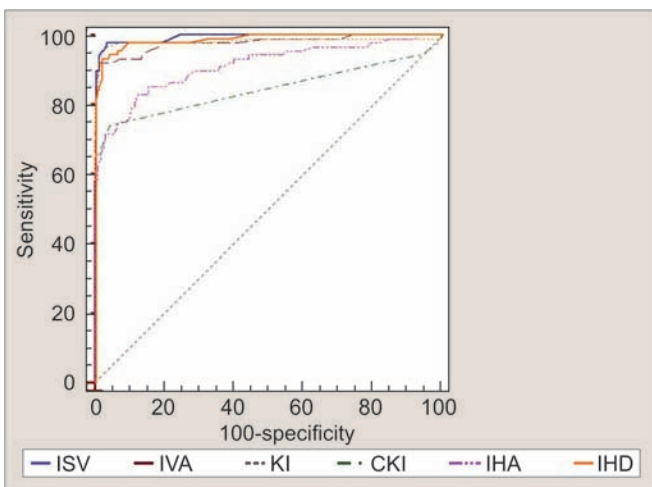


Fig. 2: ROC curves for the topometric parameters

The calculated parameter from logistic regression had AUC of 0.996, with sensitivity of 97.7% and specificity of 98.7%. Table 3 contains the coefficients for the regression formula.

There were four false negative cases among the keratoconic cases on the TKC classification (4.54%) and 16 false positive cases among normal (7.08%), so that the sensitivity and specificity of the TKC were 95.54 and 92.92% respectively. Figures 3A and B show the sagittal curvature maps of false positive cases and Figures 4A and B illustrate examples of false-negative eyes.

DISCUSSION

In this study we analyzed topometric indices derived from the front surface curvature of the cornea. While these

parameters, provided by the Pentacam comprehensive eye scanner, accurately discriminated keratoconus from normal corneas, this is fundamental for the clinician to recognize and expect a low number of false negatives and false positives. In this series, 4.54% false negative classifications and 7.08% false-positives were detected. This data may have important medicolegal relevance. Moreover, this is important for clinicians understand these automated classifications have limitations and should not be considered as a diagnostic dogma.

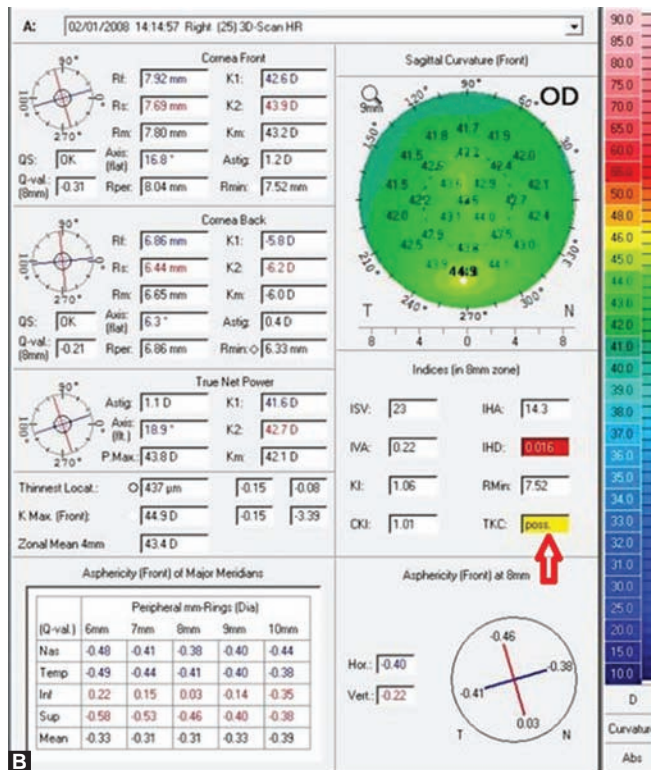
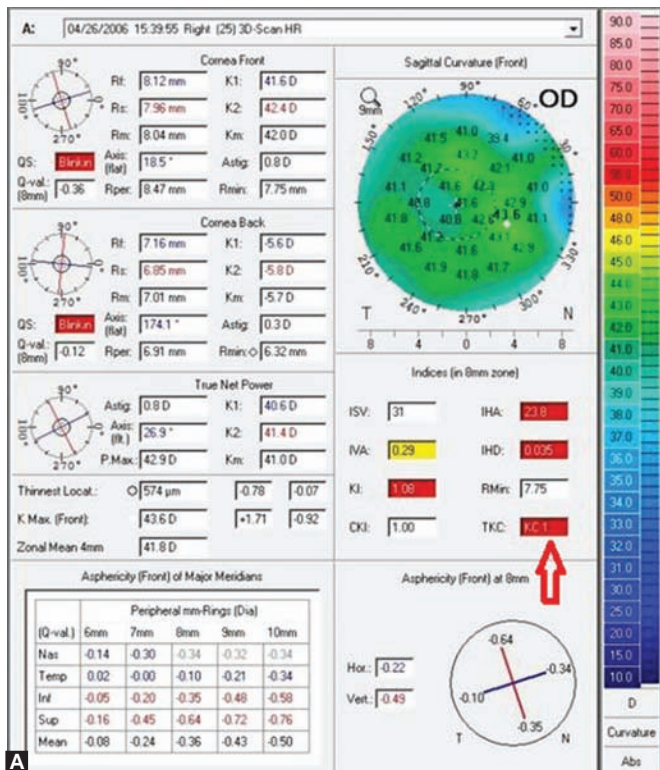
This study compared cases with clinical keratoconus and with normal corneas. The predicted accuracy of the topometric indices should not be expected among cases with milder or very early forms of the disease, such as the fellow eyes of very asymmetric keratoconus with relatively normal corneal exams. Such cases with forme fruste keratoconus typically have relatively normal indices and the accuracy of the TKC and the novel regression parameter should be tested in future studies.

Corneal tomography provides measurements of both anterior and posterior corneal surfaces, along with a pachymetric map, allowing a three-dimensional reconstruction of the cornea. Therefore, this approach provides more information than anterior surface topography and might enhance the diagnosis of milder forms of KC. Our study demonstrated the need to enhanced diagnostic tests based on tomographic 3D evaluation.¹⁶⁻¹⁹

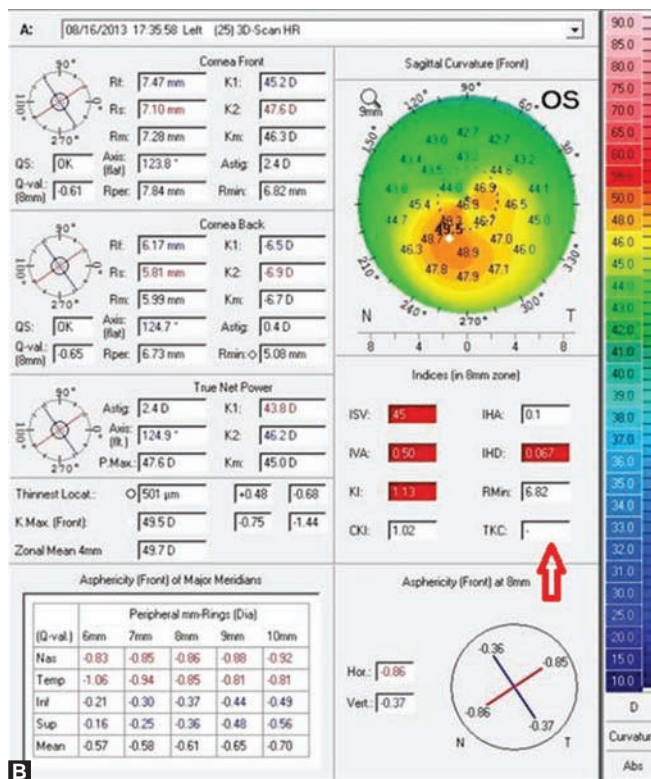
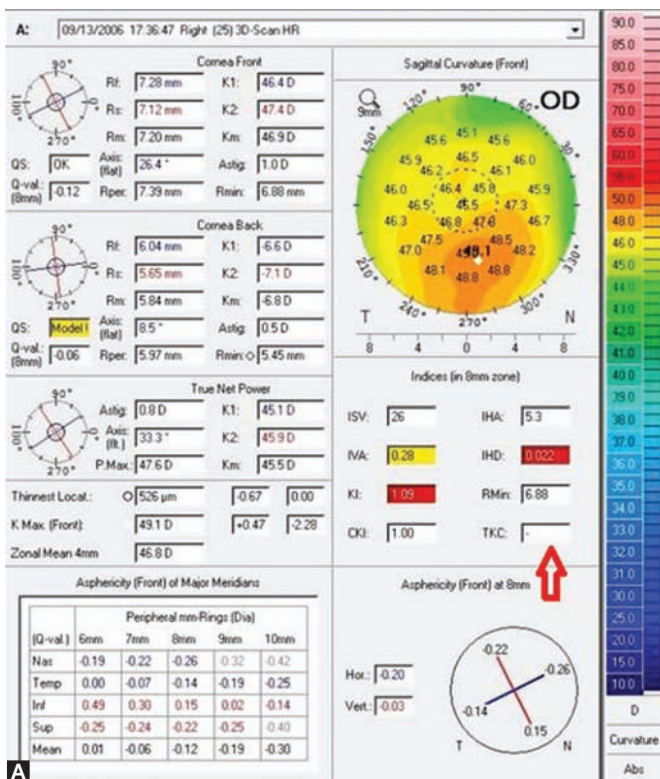
Further studies are still necessary to evaluate if the severity score of the topometric indices are clinically valid

Table 3: Coefficients used for the regression formula

Variable	ISV	IVA	KI	CKI	IHA	IHD	Constant
Coefficient	-0.0256	12.00708	36.68796	54.25196	0.15495	-14.1968	-100.485



Figs 3A and B: False-positive cases. Note that the TKC system identifies keratoconus grade 1 in (A) and possible keratoconus in (B) (arrows)



Figs 4A and B: False-negative cases. Note that the TKC system (arrows) was unable to identify keratoconus in either case

and new asphericity parameters are under test to improve the topometric functions. Studies are also needed to test the sensitivity of both topometric and enhanced tomographic parameters to detect milder forms of KC when screening ectasia risk in LASIK candidates. Correlation of these parameters with corneal biomechanical analysis may further improve the detection of very early forms of KC.

REFERENCES

1. Krachmer JH, Feder RS, Belin MW. Keratoconus and related noninflammatory corneal thinning disorders. *Surv Ophthalmol* 1984;28(4):293-322.
2. Rabinowitz YS. Keratoconus. *Surv Ophthalmol* 1998;42(4):297-319.
3. Randleman JB, Russell B, Ward MA, et al. Risk factors and prognosis for corneal ectasia after LASIK. *Ophthalmology* 2003;11:267-275.
4. Amsler M. The forme fruste of keratoconus. *Wien Klin Wochenschr* 1961;73:842-843.
5. Klyce SD. Computer-assisted corneal topography. High resolution graphic presentation and analysis of keratoscopy. *Invest Ophthalmol Vis Sci* 1984;25(12):1426-1435.
6. Wilson SE, Lin DT, Klyce SD. Corneal topography of keratoconus. *Cornea* 1991;10(1):2-8.
7. Holladay JT. Keratoconus detection using corneal topography. *J Refract Surg* 2009;25(Suppl):S958-962.
8. Maeda N, Klyce SD, Smolek MK, Thompson HW. Automated keratoconus screening with corneal topography analysis. *Invest Ophthalmol Vis Sci* 1994;35(6):2749-2757.
9. Rabinowitz YS, McDonnell PJ. Computer-assisted corneal topography in keratoconus. *Refract Corneal Surg* 1989;5(6):400-408.
10. Ambrósio R Jr, Klyce SD, Wilson SE. Corneal topographic and pachymetric screening of keratorefractive candidates. *J Refract Surg* 2003;19(1):24-29.
11. Oshika T, Klyce SD. Corneal topography in LASIK. *Semin Ophthalmol* 1998;13(2):64-70.
12. Ambrósio R Jr, Wilson SE. Complications of laser in situ keratomileusis: Etiology, prevention and treatment. *J Refract Surg* 2001;17(3):350-379.
13. Randelman JB, Woodward M, Lynn MJ, Stulting RD. Risk assessment for ectasia after corneal refractive surgery. *Ophthalmology* 2008;115(1):37-50.
14. Binder PS, Trattler WB. Evaluation of a risk factor scoring system for corneal ectasia after LASIK in eyes with normal topography. *J Refract Surg* 2010;26(4):241-250.
15. Wagner H, Barr JT, Zadnik K. Collaborative longitudinal evaluation of keratoconus (CLEK) study: methods and findings to date. *Cont Lens Anterior Eye* 2007;30(4):223-232.
16. Luz A, Ursulino M, Castaneda D, Ambrósio R Jr. Corneal thickness progression from the thinnest point to the limbus: Study based on a normal and a keratoconus population to create reference values. *Arquivos Brasileiros de Oftalmologia* 2006;69(4):579-583.
17. Ambrósio R Jr, Alonso RS, Luz A, Coca Velarde LG. Cornea thickness spatial profile and corneal volume distribution: Tomographic indices to detect keratoconus. *J Cataract Refract Surg* 2006;32(11):1851-1859.
18. Ambrósio R Jr, Caiado AL, Guerra FP, Louzada R, Roy AS, Luz A, et al. Novel pachymetric parameters based on corneal

tomography for diagnosing keratoconus. *J Refract Surg* 2011;27(10):753-758.

19. Belin MW, Khachikian SS. An introduction to understanding elevation-based topography: how elevation data are displayed – a review. *Clin Experiment Ophthalmol* 2009;37(1):14-29.

ABOUT THE AUTHORS

Marcella Q Salomao (Corresponding Author)

Clinician Scientist, Department of Ophthalmology, Rio de Janeiro Corneal Tomography and Biomechanics Study Group, Federal University of São Paulo, São Paulo, Brazil, Phone: 2132825128 e-mail: marcella@nhtelecom.com.br

Frederico P Guerra

Clinician Scientist, Department of Ophthalmology, Rio de Janeiro Corneal Tomography and Biomechanics Study Group, Federal University of São Paulo, São Paulo, Brazil

Isaac C Ramos

Clinician Scientist, Department of Ophthalmology, Rio de Janeiro Corneal Tomography and Biomechanics Study Group, Federal University of São Paulo, São Paulo, Brazil

Livia F Jordao

Clinician Scientist, Department of Ophthalmology, Rio de Janeiro Corneal Tomography and Biomechanics Study Group, Federal University of São Paulo, São Paulo, Brazil

Ana Laura C Canedo

Clinician Scientist, Department of Ophthalmology, Rio de Janeiro Corneal Tomography and Biomechanics Study Group, Federal University of São Paulo, São Paulo, Brazil

Bruno F Valbon

Clinician Scientist, Department of Ophthalmology, Rio de Janeiro Corneal Tomography and Biomechanics Study Group, Federal University of São Paulo, São Paulo, Brazil

Allan Luz

Clinician Scientist, Department of Ophthalmology, Rio de Janeiro Corneal Tomography and Biomechanics Study Group, Federal University of São Paulo, São Paulo, Brazil

Rosane Correa

Clinician Scientist, Department of Ophthalmology, Rio de Janeiro Corneal Tomography and Biomechanics Study Group, Federal University of São Paulo, São Paulo, Brazil

Bernardo Lopes

Clinician Scientist, Department of Ophthalmology, Rio de Janeiro Corneal Tomography and Biomechanics Study Group, Federal University of São Paulo, São Paulo, Brazil

Renato Ambrósio Jr

Clinician Scientist, Department of Ophthalmology, Rio de Janeiro Corneal Tomography and Biomechanics Study Group, Federal University of São Paulo, São Paulo, Brazil