

# INTACS 210° in Post-LASIK Ectasia: Follow-up of Clinical and Biomechanical Changes

Maria Ximena Nuñez, Claudia Blanco

## ABSTRACT

The authors report a case of a post-LASIK corneal ectasia with low refractive defect and progressive decreased visual acuity. INTACS SK 210° arc in 7 central millimeters was implanted, 1 year postoperative showed a decreased in maximum keratometry, vertical coma and improved visual acuity. Two years postoperative topography evidence progression of the ectasia.

**Keywords:** Intacs 210, Post-LASIK ectasia, Cornea.

**How to cite this article:** Nuñez MX, Blanco C. INTACS 210° in Post-LASIK Ectasia: Follow-up of Clinical and Biomechanical Changes. *Int J Kerat Ect Cor Dis* 2013;2(2):89-91.

**Source of support:** Nil

**Conflict of interest:** None declared

## INTRODUCTION

The progression of the corneal steep area and the deterioration in visual acuity is strongly associated with corneal ectasia as a complication of laser *in situ* keratomileusis (LASIK). This is related to the weakening of the cornea's mechanical strength.<sup>1</sup> These cases can be managed with contact lens,<sup>2</sup> intracorneal ring segments (ICRS),<sup>3-6</sup> corneal collagen cross-linking<sup>7</sup> and lamellar or penetrating keratoplasty.<sup>8,9</sup> Therapeutic options, such as ICRS like INTACS are attractive to treat post-LASIK corneal ectasia because of their reversibility, different authors have been using them,<sup>3-6</sup> but in all cases they used Intacs of 150° of arc. Reports of Ferrara rings of 210° of arc in 5 central millimeters (mm), shows that the best indications for these rings are in central cones.<sup>10</sup> This report evaluates biomechanical and clinical changes in a case of decentered post-LASIK corneal ectasia using INTACS SK 210° arc in 7 central mm.

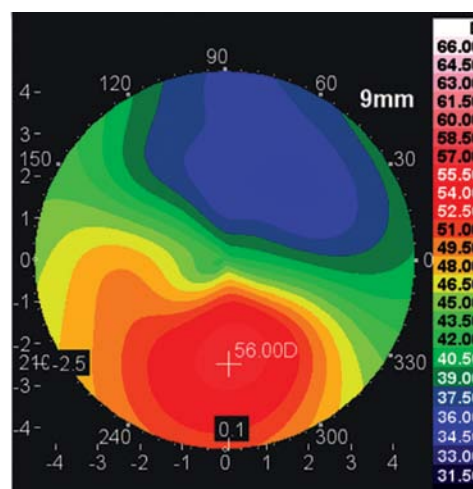
## CASE REPORT

A 29-year-old man attended in 2010 for progressive decreased visual acuity in his right eye, during the last two years, he had LASIK elsewhere 5 years before to correct

−3.75 diopters of myopia. The uncorrected distance visual acuity (UCVA) was 20/100 with a refraction of +2,25 −3.00 × 67 with a best spectacle corrected visual acuity (BSCVA) of 20/80. Corneal evaluation was performed using Keratron Scout topographer (Optikon, Rome, Italy), and GALILEI Dual Scheimpflug Analyzer (Ziemer Ophthalmic Systems, Port, Switzerland). At the axial map an inferior steepening was observed with a maximum keratometry of 56,00 Diopters and a superior flattening that occupied the superior half of the cornea as shown in Figure 1. Post-LASIK corneal ectasia, was diagnosed and intracorneal ring segment (INTACS) insertion surgery was programmed.

An INTACS SK 210° arc (AJL, Ophthalmic S, A, Miñano, Spain) was implanted in a tunnel of central 7 mm inferiorly in a depth attempt of 80% with an automated vacuum centering guide (AJL, Ophthalmic S, A, Miñano, Spain) according to INTACS Nomogram 2.2.

Three months after INTACS insertion corneal cross-linking was proposed, but the patient did not accept the procedure. Then a clinical follow-up had been realized yearly (Table 1).



**Fig. 1:** Preoperative right eye axial map shows a post-LASIK corneal ectasia, in 2010

**Table 1:** Clinical and topographical follow-up

	2010	2011	2012	2013
UCVA	20/100	20/60	20/60	20/60
BSCVA	20/40	20/30	20/30	20/30
Refraction	+2,25-3,00 x 67	+0,25-2,25 x 70	+0,75-2,25 x 70	+1,25-2,25 x 65
Z(3,-1)	-3,76	-2,07	-2,02	-2,17
Flat Sim K	41,87 x 47	40,02 x 66	38,35 x 52	39,04 x 65
Steep Sim K	43,62 x 137	42,48 x 156	40,44 x 142	40,81 x 155

UCVA: Uncorrected distance visual acuity; BSCVA: Best spectacle corrected visual acuity; Z(3-1): Corneal vertical coma; Flat Sim K: Flat simulated keratometry; Steep Sim K: Steep simulated keratometry.

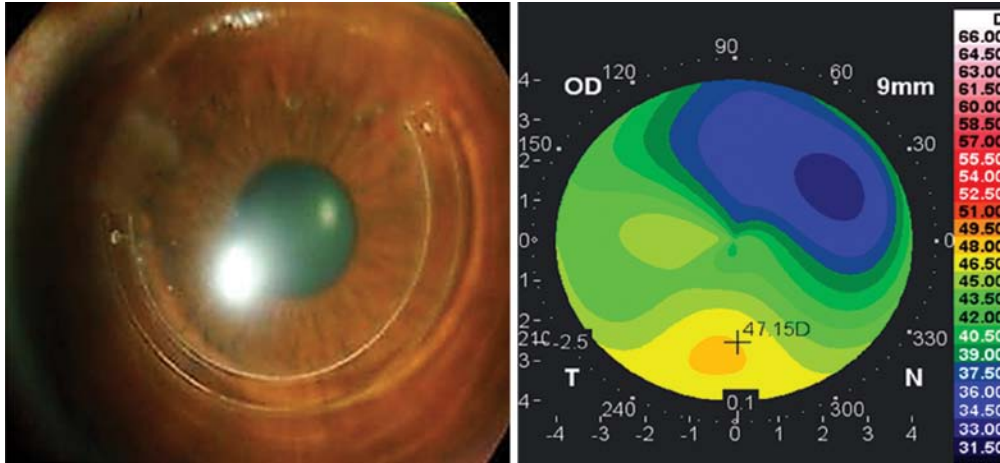


Fig. 2: Post-ICRS photograph and axial map 1 year postoperative (2011)

One year postoperative a satisfied result was achieved, with a decreased of the  $K_{max}$  at the inferior steepening of 8.85 diopters (Fig. 2), and in the wavefront analysis a decrease in the vertical coma from  $-3.76$  to  $-2.07$  microns. During the second and third year the clinical and tomographic evaluation revealed a progression of the ectasia with an increase of the steepest area (Figs 3 and 4). The BSCVA has been stable, with 20/30 for 3 years postoperatively.

**DISCUSSION**

ICRS has been used to remodel the shape of the ectatic cornea, in order to delay or avoid a corneal transplant. In post-LASIK ectasia besides anatomical reconstruction, we look for the stabilization of the cornea, adding cross-linking as a complementary procedure.

Our findings of decreased  $K_{max}$ , 1 year postoperative after ICRS implantation with evident remodeling of the cornea, with an improve in 1 line in UCVA and 3 lines in BSCVA (Fig. 2), shows us, the efficacy of the INTACS SK 210° arc in 7 central mm, in decentered ectasia as a first case reported because the cases of 210 of ICRS reported were in central keratoconus and in pellucid marginal corneal degeneration.<sup>10,11</sup> Other authors found good results in post-LASIK ectasia using one inferior 150° ring segment.<sup>12-15</sup>

We found refractive stability 3 years after ICRS implantation similar to Kymionis et al<sup>5</sup> who published it after 5 years, but in our case we find out in the axial map a progression toward ectasia, analyzing the steepest ectatic area (Figs 3 and 4).

Unfortunately in this case cross-linking was not performed to achieve stabilization of the disease, as the report of Poli M et al,<sup>16</sup> who did corneal collagen cross-linking with UVA-riboflavin in 8 post-LASIK ectasia patients and could stabilize the progression after 3 years of follow-up. In the literature there are two report cases using sequential ICRS and cross-linking treatments<sup>17,18</sup> obtaining good results in corneal stability.

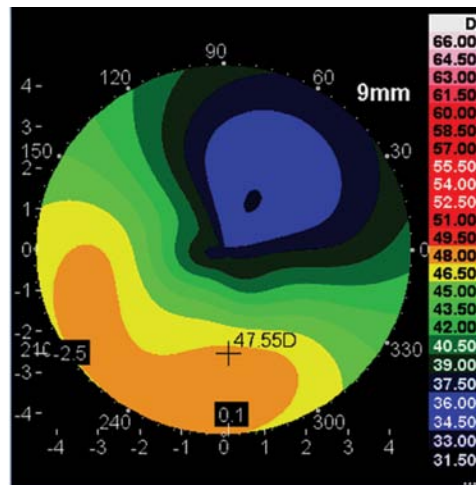


Fig. 3: Second year postoperative (2012)

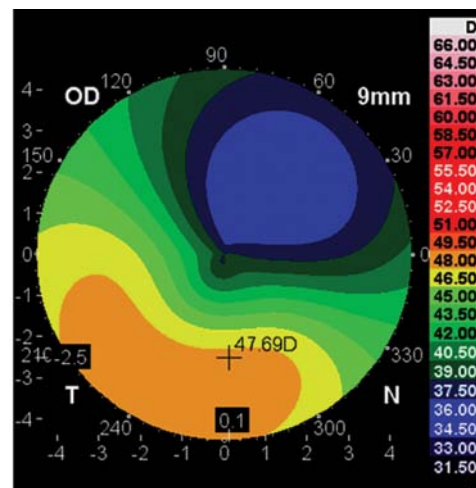


Fig. 4: Third year postoperative (2013)

**CONCLUSION**

In this case, it was effective to use INTACS SK 210° arc in 7 central mm in a decentered post-LASIK corneal ectasia with a low refractive defect. And because of the evident progressive ectasia, it would be better to do an additional early cross-linking.

## REFERENCES

1. Seiler T, Quirke AW. Iatrogenic keratectasia after LASIK in a case of forme fruste keratoconus. *J Cataract Refract Surg* 1998; 24:1007-1009.
2. Fernandez-Velazquez FJ. Kerasoft IC compared to Rose-K in the management of corneal ectasias. *Cont Lens Anterior Eye* 2012 Aug;35(4):175-179.
3. Brenner LF, Alió JL, Vega-Estrada A, Baviera J, Beltrán J, Cobo-Soriano R. Indications for intrastromal corneal ring segments in ectasia after laser in situ keratomileusis. *J Cataract Refract Surg* 2012 Dec;38(12):2117-2124.
4. Piñero DP, Alió JL, Uceda-Montanes A, Kady El B, Pascual I. Intracorneal ring segment implantation in corneas with post-laser in situ keratomileusis keratectasia. *Ophthalmology* 2009; 116:1665-1674.
5. Kymionis GD, Tsiklis NS, Pallikaris AI, Kounis G, Diakonis VF, Astyrakakis N, Siganos CS. Long-term follow-up of Intacs for post-LASIK corneal ectasia. *Ophthalmology* 2006; 113:1909-1917.
6. Ertan A, Colin J. Intracorneal rings for keratoconus and keratectasia. *J Cataract Refract Surg* 2007;33:1303-1314.
7. Hafezi F, Kanellopoulos J, Wiltfang R, Seiler T. Corneal collagen crosslinking with riboflavin and ultraviolet A to treat induced keratectasia after laser in situ keratomileusis. *J Cataract Refract Surg* 2007 Dec;33(12):2035-2040.
8. Kucumen RB, Yenerel NM, Gorgun E, Oncel M. Penetrating keratoplasty for corneal ectasia after laser in situ keratomileusis. *Eur J Ophthalmol* 2008;18:695-702.
9. Javadi MA, Feizi S, Yazdani S, Mirbabae F. Deep anterior lamellar keratoplasty versus penetrating keratoplasty for keratoconus: a clinical trial. *Cornea* 2010;29:365-371.
10. Ferrara P, Torquetti L. Clinical outcomes after implantation of a new intrastromal corneal ring with a 210-degree arc length. *J Cataract Refract Surg* 2009;35:1604-1608.
11. Kubaloglu A, Sari ES, Cinar Y, Koytak A, Kurnaz E, Piñero DP, Ozerturk Y. A single 210-degree arc length intrastromal corneal ring implantation for the management of pellucid marginal corneal degeneration. *Am J Ophthalmol* 2010 Aug;150(2):185-192.
12. Alió JL, Salem TF, Artola A, Osman AA. Intracorneal rings to correct corneal ectasia after laser in situ keratomileusis. *J Cataract Refract Surg* 2002;28:1568-1574.
13. Lovisolo CF, Fleming JF. Intracorneal ring segments for iatrogenic keratectasia after laser in situ keratomileusis or photorefractive keratectomy. *J Refract Surg* 2002;18:535-541.
14. Kymionis GD, Siganos CS, Kounis G, et al. Management of post-LASIK corneal ectasia with Intacs inserts; one-year results. *Arch Ophthalmol* 2003;121:322-326.
15. Pokroy R, Levinger S, Hirsh A. Single INTACS segment for postlaser in situ keratomileusis keratectasia. *J Cataract Refract Surg* 2004;30:1685-1695.
16. Poli M, Cornut PL, Balmitgere T, Aptel F, Janin H, Burillon C. Prospective study of corneal collagen cross-linking efficacy and tolerance in the treatment of keratoconus and corneal ectasia: 3-year results. *Cornea* 2013 May;32(5):583-590.
17. Lam K, Rootman DB, Lichtinger A, Rootman DS. Post-LASIK ectasia treated with intrastromal corneal ring segments and corneal crosslinking. *Digit J Ophthalmol* 2013 Jan 6;19(1):1-8.
18. Kamburoglu G, Ertan A. Intacs implantation with sequential collagen cross-linking treatment in postoperative LASIK ectasia. *J Refract Surg* 2008 Sep;24(7):S726-729.

## ABOUT THE AUTHORS

## Maria Ximena Nuñez

Cornea and Refractive Surgery Unit, Vision Sana Research Group Clínica de Oftalmología de Cali; Professor of Faculty of Medicine Pontificia Universidad Javeriana-Cali, Cali, Colombia, South America

**Correspondence Address:** Cra 47 sur # 8 C 94 office 223, Cali Colombia, South America, Phone: 57(2)5110898, Fax: 57(2) 5520896 e-mail: ximena@visionsana.com

## Claudia Blanco

Cornea and Refractive Surgery Unit, Vision Sana Research Group Clínica de Oftalmología de Cali; Professor of Faculty of Medicine Pontificia Universidad Javeriana-Cali, Cali, Colombia, South America