

Keratoconus associated with Corneal Guttata

Isaac C Ramos, Michael W Belin, Bruno F Valbon, Allan Luz, Leonardo N Pimentel
Diogo L Caldas, Renato Ambrósio Jr

ABSTRACT

Purpose: To describe clinical findings of cases with keratoconus and concomitant corneal guttata.

Setting: Rio de Janeiro Corneal Tomography and Biomechanics Study Group, Brazil.

Materials and methods: In a retrospective study including 138 patients with clinical keratoconus, 22 eyes from 11 (8%) patients with keratoconus were identified with the presence of corneal guttata. Complete ophthalmologic examination was performed in all patients, including Scheimpflug rotation tomography (Pentacam HR, Oculus, Wetzlar, Germany), biomechanical study associated with noncontact tonometry [ocular response analyzer (ORA); Reichert, Depew, USA], and specular microscopy (LSM 12000, Bio-Optics, Oregon, USA). The amount of guttata was correlated with biomechanical and tomographic parameters by nonparametric Spearman test.

Results: The mean age was 51.8 ± 20.9 (from 25 to 81) years, nine patients were female (81.9%). The mean of corrected distance visual acuity was 0.20 (20/32) ± 0.49 [from 0 (20/20) to 1.9 (10/800)] LogMar. Eleven eyes had corneal guttae grade I, six eyes grade II, four eyes grade III, and one eye grade IV. The average central keratometric readings were 44.45 ± 2.54 (from 39.70 to 50.60) for flattest K (K1), 46.08 ± 2.69 (from 42.40 to 53.50) for steepest K (K2) and 45.24 ± 2.52 (from 42.00 to 52.20) for average K (Km). Maximal keratometric value (K_{max}) averaged 47.63 ± 3.10 (from 43.5 to 55.8) D. The mean CCT was 482.54 ± 52.13 μm (from 398 to 585) and in the thinnest point 474.45 ± 50.32 μm (from 387 to 577). The mean of pachymetric progression indices were 0.83 ± 0.41 (from 0.2 to 2.03) (PPI Min), 1.24 ± 0.53 (from 0.7 to 2.73) (PPI Avg), and 1.79 ± 0.92 (from 0.88 to 4.67) (PPI Max). The mean of ART Min was 710.54 ± 372.47 (from 190.64 to 1985), of ART Avg was 433.18 ± 140.96 (from 141.75 to 678.37), and of ART Max was 315.64 ± 122.69 (from 102.78 to 539.78). The mean of front and back elevation at the thinnest point (using best fit sphere to 8 mm) was 5.35 ± 6.77 (from -4 to 20) and 19.15 ± 16.41 (from 1 to 50) respectively. Belin-Ambrósio deviation index (BAD D) was 3.05 ± 3 (from -0.34 to 11.55). The mean corneal hysteresis (CH) was 8.23 ± 2.05 (from 4.1 to 10.9), corneal resistance factor (CRF) was 7.67 ± 2.4 (from 3.4 to 11.3). The amount of guttata was statistically correlated with Km and K1 (Spearman, $p > 0.05$).

Conclusion: Keratoconus and cornea guttata can coexist in the same patient. This association can camouflage corneal thinning and protrusion associated with ectasia, but elevation, relational thickness, along with combined tomographic indices and biomechanical properties are altered. The diagnosis should be considered in the complete ophthalmic examination, including corneal topography, and tomographic characterization, along specular documentation of corneal endothelium.

Keywords: Keratoconus, Ectasia, Guttata, Fuchs, Dystrophy, Corneal biomechanic.

How to cite this article: Ramos IC, Belin MW, Valbon BF, Luz A, Pimentel LN, Caldas DL, Ambrósio R Jr. Keratoconus associated with Corneal Guttata. *Int J Kerat Ect Cor Dis* 2012;1(3):173-178.

Source of support: Nil

Conflict of interest: None declared

INTRODUCTION

Keratoconus is described as a bilateral noninflammatory ectatic corneal disorder.¹ It is characterized by progressive paracentral thinning of the stroma with protrusion of the cornea, so as to assume a conical shape. Keratoconus usually appears between the second and third decades of life and has an estimated incidence of 1:2,000.¹ It is characterized by progressive myopia and astigmatism with a variable degree of irregularity, which leads to decreased uncorrected and spectacle corrected visual acuity. The etiology is multifactorial, and it is believed that eye rubbing and allergic processes are possible causes of or worsening of keratoconus in patients genetically susceptible.¹⁻⁴

Keratoconus can occur with other corneal dystrophies, and Fuchs dystrophy is the most common.⁵⁻⁹ Fuchs dystrophy is also bilateral, may be markedly asymmetric, affects more females (4:1), and has a pattern of autosomal dominant inheritance.¹⁰⁻¹⁴ Fuchs' dystrophy is initially characterized by the appearance of corneal guttata, which are focal accumulations of collagen in the posterior surface of Descemet's membrane. These lesions arise from endothelial cells with abnormal metabolism and show up as small blisters or protuberances rounded toward the endothelium. In specular reflection biomicroscopy Fuchs appear as small dark spots resulting from the breakdown of regular endothelial mosaic, and in backlight illumination resemble dew drops. With the advancement of the disease, the guttata coalesce and Descemet's membrane becomes thickened and irregular. Endothelial function is eventually compromised leading to stromal edema.^{10,14-17}

The aim of this paper is to describe the clinical findings, including tomographic parameters of a series of cases of keratoconus associated with corneal guttata.

PATIENTS AND METHODS

In a retrospective study, among 138 patients with clinical keratoconus, 22 eyes of 11 patients (8.0%) were identified with the presence of corneal guttata.

Complete ophthalmologic examinations were performed in all patients, including distance corrected visual acuity (DCVA), slit lamp biomicroscopy, tonometry and biomechanical measurements with noncontact tonometry

[ocular response analyzer (ORA); Reichert, Depew, USA], dilated fundus, Scheimpflug rotational tomography (Pentacam HR, Oculus, Wetzlar, Germany), and specular microscopy (LSM 12000, Bio-Optics, Oregon, USA).

Inclusion criteria were patients with diagnosis of bilateral keratoconus and concomitant presence of corneal guttata. Cases that had any type of prior surgery were excluded from this study.

Keratoconus was diagnosed based on a comprehensive clinical evaluation, including biomicroscopy, Placido's topography and corneal and anterior segment tomography. Cornea guttata was detected at biomicroscopy, and their degree of severity was subsequently assessed by specular microscopy (classification according to Laing)¹⁸ and Pentacam Scheimpflug images.

Clinical parameters analyzed were: Age, sex, race, family history, CDVA, severity of guttata, keratometric readings [flattest K (K1), steepest K (K2), average K (Km), and K maximum (K_{max})], pachymetric measurements at the center (CCT), thinnest point (TP), the pachymetric progression indices [minimum (PPI Min), average (PPI Avg) and maximum (PPI Max)], the Ambrósio relational thickness [minimum (ART Min), average (ART Avg) and maximum (ART Max)]¹⁹, the graphs of the pachymetric progression profile [corneal thickness spatial profile (CTSP)] and [percentage increase thickness (PIT)]¹⁹⁻²¹, front and back elevation at the thinnest point using the best fit sphere (BFS) reference for the 8 mm zone²², the Belin-Ambrósio deviation index (BAD D)²³, and the pressure-derived parameters from ORA²⁴ [corneal hysteresis (CH) and corneal resistance factor (CRF)].

All data were tabulated on excel spreadsheet (Microsoft Office 2007). The degree of guttata was correlated with the degree of severity of keratoconus, and tomographic parameters by Spearman test.

RESULTS

The average age of patients at diagnosis was 51.8 ± 20.9 years (range, 25-81 years). Nine patients were females (81.9%) and two were males (18.1%). Ten patients were Caucasian (90.9%) and one patient was of the black race (9.1%). No patient had known family history of keratoconus or corneal disease. The mean of CDVA was 0.20 (20/32) \pm 0.49 [from 0 (20/20) to 1.9 (10/800)] LogMar. The degrees of guttata were: Grade I in 11 eyes, grade II in six eyes, grade III in four eyes, and grade IV in one eye.

The mean of keratometric readings were 44.45 ± 2.54 D (range: 39.70-50.60 D) for K1, 46.08 ± 2.69 D (range: 42.40-53.50) for K2, 45.24 ± 2.52 D (range: 42.00-52.20) for Km, and 47.63 ± 3.10 D (range: 43.50-55.80 D) for K_{max} .

The mean and standard deviation of pachymetric measures were: CCT = 482.54 ± 52.13 μ m (range: 398-585 μ m), TP = 474.45 ± 50.32 μ m (range: 387-577 μ m) and Pachy apex = 482.54 ± 52.76 μ m (range 392-584 μ m); PPI Min = 0.83 ± 0.41 (range: 0.2-2.03); PPI Avg = 1.24 ± 0.53 (range: 0.7-2.73) and PPI Max = 1.79 ± 0.92 (range: 0.88-4.67). The mean of ART Min was 710.54 ± 372.47 (range: 190.64-1985), of ART Avg was 433.18 ± 140.96 (range: 141.75-678.37), and of ART Max was 315.64 ± 122.69 (range: 102.78-539.78).

The mean front and back elevation at the thinnest point (using best fit sphere to 8 mm) was 5.35 ± 6.77 (range: -4 to 20) and 19.15 ± 16.41 (range: 1 to 50) respectively.

The Belin-Ambrósio deviation index (BAD D) was 3.05 ± 3 (range: -0.34 to 11.55).

The mean ORA pressure-derived parameters were: CH = 8.23 ± 2.05 (range: 4.1-10.9) and CRF = 7.67 ± 2.4 (range: 3.4-11.3).

The degree of guttata was statistically correlated (Spearman, $p < 0.05$) with the average central keratometric (Km, $r_s = -0.39$) reading and flat central simulated keratometric reading (Flattest K or K1, $r_s = -0.41$).

DISCUSSION

The presence of concomitant keratoconus and corneal guttata may occur. Genetic studies have evaluated the association of keratoconus with Fuchs' dystrophy, but the details of both have not been fully elucidated.²⁵⁻²⁹

In this study, a significant correlation was found between the amount of guttata and the central keratometric readings. Also, thinning of the cornea caused by keratoconus and corneal thickening consequent to endothelial dysfunction, can combine to normalize corneal pachymetry.⁶ CCT varies widely in the normal population, with some differences in populations of different regions.^{30,31} Normal values of 545 μ m with a standard deviation of 35 were previously found in a normal Brazilian population.³² The average among the 22 eyes with keratoconus and guttata was 482.54 ± 52.13 μ m, lower than the measures reported by Azar and Jurkunas of 543 μ m, and Cremona et al of 557.6 μ m in a similar series of patients with coexistent keratoconus and Fuchs.^{6,8} The difference may be secondary to the fact that in our study 77.2% of eyes had mild guttata (grade I or II), therefore, less subclinical swelling and less corneal thickness. If we look only at the CCT measurements, one or both diagnosis may be missed, or the severity of either may be underestimated.

Tomography allows for the construction of maps that characterize the front and back elevation of the cornea, along with a full corneal thickness map and pachymetric progression profiles.³³ Significant differences exist in the spatial distribution of thickness between normal and

keratoconus corneas,^{20,21} and between normal and Fuchs’s dystrophy cases.³⁴ Keratoconus presents with a pattern of more abrupt thickening from the thinnest point toward the periphery, while the opposite is observed in the evaluation of corneal edema.³⁴ The pachymetric progression indices (PPI Min, PPI Ave and PPI Max) indices may be changed in the two situations, showing increased in the ectasias and decreased in the case of edema. The combination of keratoconus and Fuchs, however, may mask or even normalize these changes when either pathologic conditions are relatively mild.

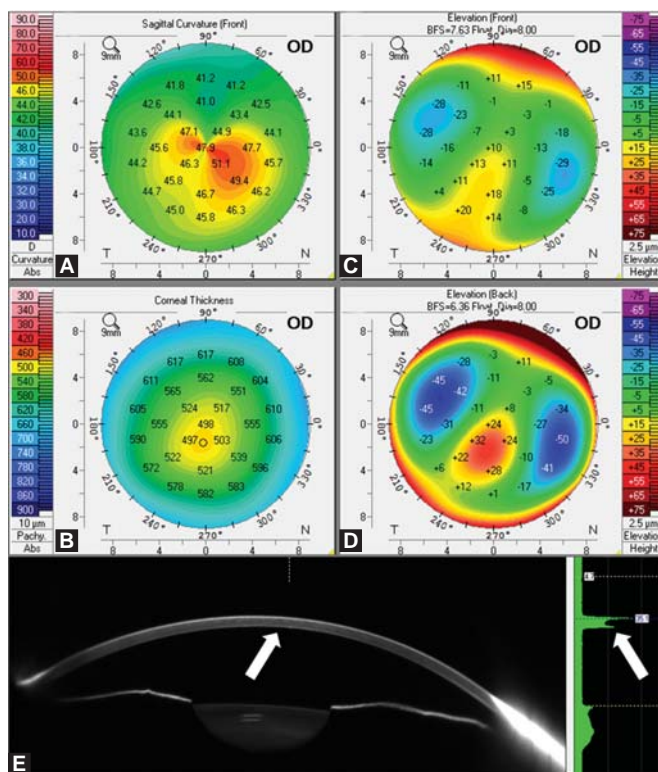
In our study, rotating Scheimpflug analysis of patients with keratoconus and corneal guttata showed keratometric readings, curvature and elevation maps, typical of keratoconus (Figs 1A to D). CCT values, however, were near to normal, and the pachymetric progression graphs showed a pattern of thinning and abrupt increase typical of edema. This characteristic has a deviation from the curve of the mean normal population in the PTI graph in the opposite (Figs 2A to C). Despite the presence of corneal guttata, the mean of pachymetric progression indices were increased (Table 1). The Scheimpflug image shows a higher reflectivity of Descemet’s membrane which presents itself as a second peak in the graph of the density of the cornea.

This finding is typical of cornea guttata and is called camel’s sign (Fig. 1E).³⁴

It is described decrease in endothelium hexagonal cells of patients with keratoconus, but with normal density.^{35,36} In our study, the patients presented in specular microscopy an abnormal endothelial mosaic (pleomorphism and polymegathism) with large areas of excrescences (Fig. 3).

The ORA uses a pulse of air which is applied directly to the cornea, and through an electro-optical coupling dynamically monitors the corneal flattening. The two phases of flattening of the cornea are measured and correlated with the air pressure exercised. The difference in measured pressures during both flattening phases reflects the tissue’s ability to absorb energy, and is called the corneal hysteresis (CH; Fig. 4). The CRF is a measure of the cumulative effects of corneal viscous and elastic resistance encountered by the air during the process.^{24,37}

Fontes and coauthors reported values of CH and CRF statistically lower in keratoconus (normal: CH = 10.17 ± 1.82 and CRF = 10.14 ± 1.80; keratoconus: CH = 9.22 ± 1.44 and CRF = 8.62 ± 1.52).^{32,38} Another study reports the values of CH and CRF also reduced by Fuchs’ dystrophy.³⁹ In our study the cases with concomitant keratoconus and cornea guttata presented CH and CRF of 8.23 ± 2.05 and 7.67 ± 2.40 respectively. These values are lower than reported for either normal or keratoconic corneas and can indicate that the association of both diseases could lead to a greater reduction of corneal biomechanical measurements.



Figs 1A to E: Pentacam exam of a patient with keratoconus and corneal guttata. A to D—quad refractive display: Curvature map (A), pachymetric map; (B) and elevation maps (C and D); (E) Scheimpflug image: Indicating increased reflectivity of Descemet’s membrane (left arrow) and the camel sign (right arrow), both characteristics of corneal guttata

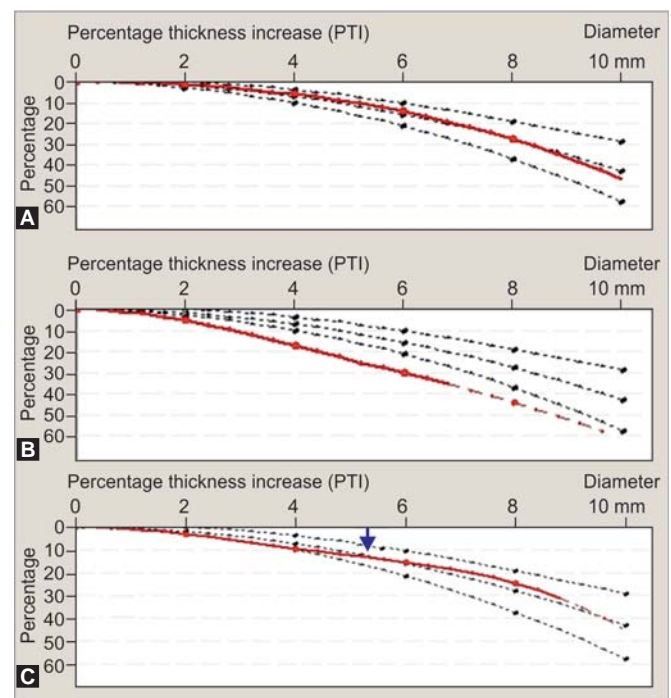


Fig. 2: PTI graphs: (A) Normal, (B) keratoconus, (C) keratoconus associated with corneal guttata (arrow indicating the abrupt change in the pachymetric progression)

Table 1: Main tomographic parameters of normal, keratoconus,⁴⁰ and keratoconus associated with corneal guttata

	Normal*				Keratoconus*				Keratoconus associated corneal guttata			
	Mean	SD	Min.	Max.	Mean	SD	Min.	Max.	Mean	SD	Min.	Max.
CCT	552.28	35.93	458.00	665.00	474.40	45.54	306.00	584.00	482.50	52.10	398.00	585.00
Thinnest point	549.23	35.47	454.00	660.00	459.06	47.6	296.00	568.00	474.40	50.30	387.00	577.00
K _m max (front)	44.57	1.50	40.80	48.80	54.00	6.92	43.00	86.10	47.63	3.10	43.50	55.80
PPI Avg	0.85	0.11	0.60	1.28	2.12	1.31	0.88	10.78	1.24	0.53	0.70	2.73
PPI Max	1.07	0.16	0.63	2.07	2.99	1.86	1.19	14.95	1.79	0.92	0.88	4.67
ART Avg	655.99	103.97	354.00	999.00	265.90	106.29	28.00	550.00	433.18	140.96	141.75	678.37
ART Max	526.69	90.64	219.00	908.00	192.99	83.28	21.00	432.00	315.64	122.69	102.78	539.78
Front elevation**	1.57	2.04	-6.00	7.00	22.00	13.32	-6.00	70.00	5.35	6.78	-4.00	20.00
Back elevation**	3.55	4.18	-4.00	16.00	48.86	29.30	2.00	189.00	19.15	16.41333	1.00	50.00
BAD D	0.43	0.57	-1.20	2.71	8.08	4.99	1.36	33.93	3.05	3.00	-0.34	11.55

*Faria-Correia F, Ramos I, Lopes B, Salomão MQ, Luz A, Correa RO, Belin MW, Ambrosio R Jr. Topometric and tomographic indices for the diagnosis of keratoconus. Int J Kerat Ectatic Corn Dis 2012;1:92-99; **At the thinnest point using best fit sphere to 8 mm

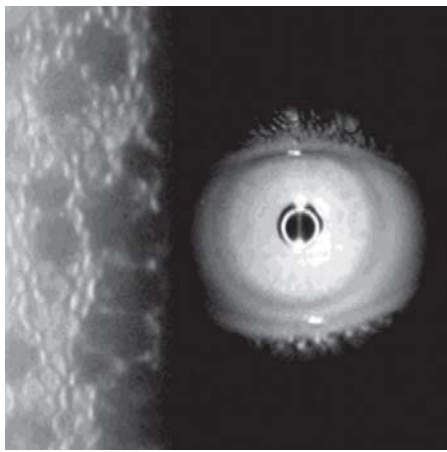


Fig. 3: Specular microscopy of a patient with keratoconus and corneal guttata: Polymegathism, pleomorphism and areas of excrescence

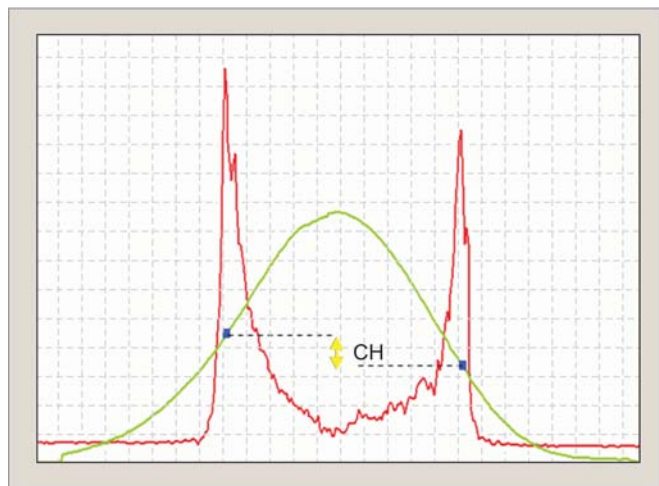
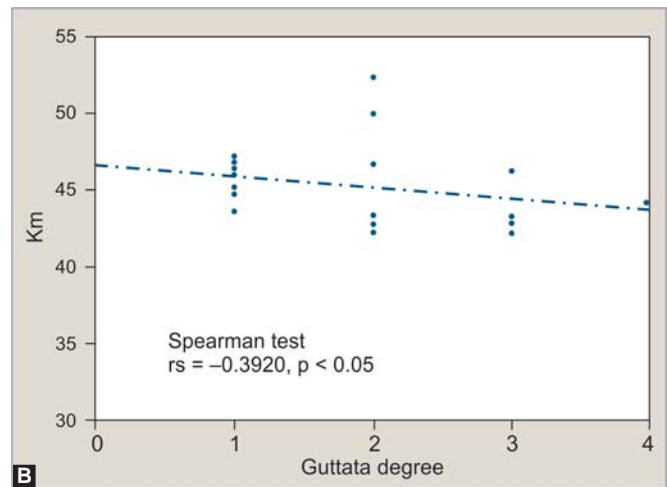
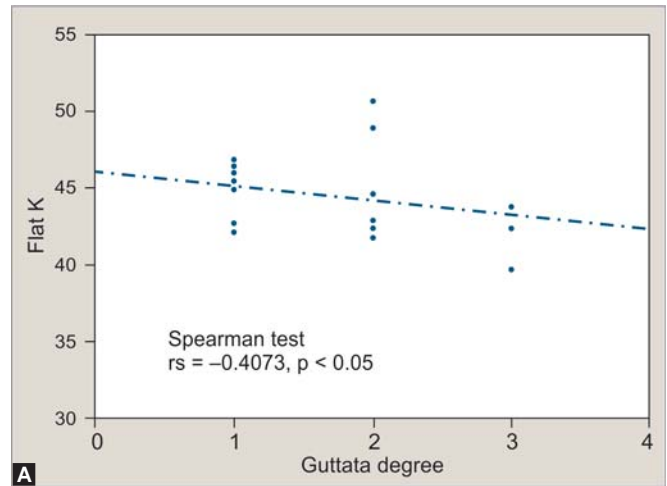


Fig. 4: The ORA demonstrating corneal hysteresis (CH)



Figs 5A and B: Spearman correlation: (A) Degree of guttata and Flat K ($r_s = -0.4073, p < 0.05$). (B) Degree of guttata and Km ($r_s = -0.3920, p < 0.05$)

It is not possible to establish quantitatively the interference of each disease in corneal biomechanics, however, despite a possible masking of the values of CCT, corneal biomechanical properties remained altered in eyes with concomitant keratoconus and corneal guttata.

There was a negative correlation between the amount of guttata and keratometric readings (Figs 5A and B), so

that the more advanced the guttata, the lower these keratometric readings (K1 and Km), suggesting less advanced keratoconus.

In cases with keratoconus associated with Fuch’s endothelial dystrophy, the CCT measurements do not represent the extent of stromal lamellae loss and endothelial function. However, tomographic and corneal biomechanical

measurements, along with specular microscopy are helpful to determine and characterize the coexistence of both diseases.

CONCLUSION

Keratoconus and cornea guttata can coexist in the same patient. This association can 'neutralize' pathologic changes that occur in both diseases, but it does not normalize biomechanical and tomographic properties. This is critical to evaluate the endothelium of keratoconus as the diagnosis should be considered in the face of a complete ophthalmic examination, supplemented by corneal tomography, biomechanical characterization, and corneal endothelium specular documentation.

REFERENCES

- Rabinowitz YS. Keratoconus. *Surv Ophthalmol* 1998;42:297-319.
- Bawazeer AM, Hodge WG, Lorimer B. Atopy and keratoconus: A multivariate analysis. *Br J Ophthalmol* 2000;84:834-36.
- Krachmer JH. Eye rubbing can cause keratoconus. *Cornea* 2004;23:539-40.
- Krachmer JH, Feder RS, Belin MW. Keratoconus and related noninflammatory corneal thinning disorders. *Surv Ophthalmol* 1984;28:293-322.
- Bron AJ, Rabinowitz YS. Corneal dystrophies and keratoconus. *Curr Opin Ophthalmol* 1996;7:71-82.
- Cremona FA, Ghosheh FR, Rapuano CJ, et al. Keratoconus associated with other corneal dystrophies. *Cornea* 2009;28:127-35.
- Darlington JK, Mannis MJ, Segal WA. Anterior keratoconus associated with unilateral cornea guttata. *Cornea* 2001;20:881-84.
- Jurkunas U, Azar DT. Potential complications of ocular surgery in patients with coexistent keratoconus and Fuchs' endothelial dystrophy. *Ophthalmology* 2006;113:2187-97.
- Lipman RM, Rubenstein JB, Torczynski E. Keratoconus and Fuchs' endothelial dystrophy. *Cornea* 1991;10:368.
- Eghrari AO, Gottsch JD. Fuchs' corneal dystrophy. *Expert Rev Ophthalmol* 2010;5:147-59.
- Gottsch JD, Sundin OH, Liu SH, et al. Inheritance of a novel COL8A2 mutation defines a distinct early-onset subtype of fuchs corneal dystrophy. *Invest Ophthalmol Vis Sci* 2005;46:1934-39.
- Krachmer JH, Bucher KD, Purcell JJ Jr, Young CW. Inheritance of endothelial dystrophy of the cornea. *Ophthalmologica* 1980;181:301-13.
- Krachmer JH, Purcell JJ Jr, Young CW, Bucher KD. Corneal endothelial dystrophy. A study of 64 families. *Arch Ophthalmol* 1978;96:2036-39.
- Schnitzer JI, Krachmer JH. A specular microscopic study of families with endothelial dystrophy. *Br J Ophthalmol* 1981;65:396-400.
- Adamis AP, Filatov V, Tripathi BJ, Tripathi RC. Fuchs' endothelial dystrophy of the cornea. *Surv Ophthalmol* 1993;38:149-68.
- Hogan MJ, Wood I, Fine M. Fuchs' endothelial dystrophy of the cornea. 29th Sanford Gifford Memorial Lecture. *Am J Ophthalmol* 1974;78:363-83.
- Rosenblum P, Stark WJ, Maumenee IH, Hirst LW, Maumenee AE. Hereditary Fuchs' Dystrophy. *Am J Ophthalmol* 1980;90:455-62.
- Laing RA, Leibowitz HM, Oak SS, Chang R, Berrospi AR, Theodore J. Endothelial mosaic in Fuchs' dystrophy. A qualitative evaluation with the specular microscope. *Arch Ophthalmol* 1981;99:80-83.
- Ambrosio R Jr, Caiado AL, Guerra FP, et al. Novel pachymetric parameters based on corneal tomography for diagnosing keratoconus. *J Refract Surg* 2011;27:753-58.
- Luz A, Ursulio M, Castaneda D, Ambrosio R Jr. [Corneal thickness progression from the thinnest point to the limbus: Study based on a normal and a keratoconus population to create reference values]. *Arq Bras Oftalmol* 2006;69:579-83.
- Ambrosio R Jr, Alonso RS, Luz A, Coca Velarde LG. Corneal-thickness spatial profile and corneal-volume distribution: Tomographic indices to detect keratoconus. *J Cataract Refract Surg* 2006;32:1851-59.
- Belin MW, Khachikian SS. An introduction to understanding elevation-based topography: How elevation data are displayed—a review. *Clin Experiment Ophthalmol* 2009;37:14-29.
- Ambrosio R Jr, Nogueira LP, Caldas DL, et al. Evaluation of corneal shape and biomechanics before LASIK. *Int Ophthalmol Clin* 2011;51:11-38.
- Luce DA. Determining in vivo biomechanical properties of the cornea with an ocular response analyzer. *J Cataract Refract Surg* 2005;31:156-62.
- Afshari NA, Mullally JE, Afshari MA, et al. Survey of patients with granular, lattice, avellino and Reis-Bucklers corneal dystrophies for mutations in the BIGH3 and gelsolin genes. *Arch Ophthalmol* 2001;119:16-22.
- Aldave AJ. VSX1 mutation and corneal dystrophies. *Ophthalmology* 2005;112:170-71.
- Aldave AJ, Sonmez B. Elucidating the molecular genetic basis of the corneal dystrophies: Are we there yet? *Arch Ophthalmol* 2007;125:177-86.
- Rabinowitz YS. The genetics of keratoconus. *Ophthalmol Clin North Am* 2003;16:607-20.
- Udar N, Kenney MC, Chalukya M, et al. Keratoconus: No association with the transforming growth factor beta-induced gene in a cohort of American patients. *Cornea* 2004;23:13-17.
- Aghaian E, Choe JE, Lin S, Stamper RL. Central corneal thickness of Caucasians, Chinese, Hispanics, Filipinos, African Americans, and Japanese in a glaucoma clinic. *Ophthalmology* 2004;111:2211-19.
- Torres RJ, Jones E, Edmunds B, Becker T, Cioffi GA, Mansberger SL. Central corneal thickness in Northwestern American Indians/Alaskan Natives and comparison with White and African-American persons. *Am J Ophthalmol* 2008;146:747-51.
- Fontes BM, Ambrosio R Jr, Alonso RS, Jardim D, Velarde GC, Nose W. Corneal biomechanical metrics in eyes with refraction of -19.00 to +9.00 D in healthy Brazilian patients. *J Refract Surg* 2008;24:941-45.
- Ambrosio R Jr, Belin MW. Imaging of the cornea: topography vs tomography. *J Refract Surg* 2010;26:847-49.

34. Kwon RO, Price MO, Price FW Jr, Ambrosio R Jr, Belin MW. Pentacam characterization of corneas with Fuchs dystrophy treated with Descemet membrane endothelial keratoplasty. *J Refract Surg* 2010;26:972-79.
35. Matsuda M, Suda T, Manabe R. Quantitative analysis of endothelial mosaic pattern changes in anterior keratoconus. *Am J Ophthalmol* 1984;98:43-49.
36. Laing RA, Sandstrom MM, Berrospi AR, Leibowitz HM. The human corneal endothelium in keratoconus: A specular microscopic study. *Arch Ophthalmol* 1979;97:1867-69.
37. Kotecha A, Elsheikh A, Roberts CR, Zhu H, Garway-Heath DF. Corneal thickness- and age-related biomechanical properties of the cornea measured with the ocular response analyzer. *Invest Ophthalmol Vis Sci* 2006;47:5337-47.
38. Fontes BM, Ambrosio R Jr, Velarde GC, Nose W. Ocular response analyzer measurements in keratoconus with normal central corneal thickness compared with matched normal control eyes. *J Refract Surg* 2011;27:209-15.
39. del Buey MA, Cristobal JA, Ascaso FJ, Lavilla L, Lanchares E. Biomechanical properties of the cornea in Fuchs' corneal dystrophy. *Invest Ophthalmol Vis Sci* 2009;50:3199-202.

ABOUT THE AUTHORS

Isaac C Ramos (Corresponding Author)

Clinician Scientist, Department of Ophthalmology, Rio de Janeiro Corneal Tomography and Biomechanics Study Group, RJ, Brazil
e-mail: isaacramos_@hotmail.com

Michael W Belin

Clinician Scientist, Department of Ophthalmology and Vision Science Southern Arizona VA Healthcare System, University of Arizona Arizona, USA

Bruno F Valbon

Clinician Scientist, Department of Ophthalmology, Rio de Janeiro Corneal Tomography and Biomechanics Study Group, RJ, Brazil

Allan Luz

Clinician Scientist, Department of Ophthalmology, Rio de Janeiro Corneal Tomography and Biomechanics Study Group, RJ, Brazil

Leonardo N Pimentel

Clinician Scientist, Department of Ophthalmology, Rio de Janeiro Corneal Tomography and Biomechanics Study Group, RJ, Brazil

Diogo L Caldas

Clinician Scientist, Department of Ophthalmology, Rio de Janeiro Corneal Tomography and Biomechanics Study Group, RJ, Brazil

Renato Ambrósio Jr

Clinician Scientist, Department of Ophthalmology, Rio de Janeiro Corneal Tomography and Biomechanics Study Group, RJ, Brazil