

# Simplified Nomenclature for describing Keratoconus

Michael W Belin, Joan T Kim, Peter Zloty, Renato Ambrosio Jr

## ABSTRACT

Keratoconus is a condition that has been described since the 1850s. It is typically defined as a bilateral, progressive, noninflammatory thinning and steepening disorder of the central or paracentral cornea. In its advanced form, diagnosis is rather straightforward. It is the subtler manifestations of keratoconus that impart a diagnostic challenge. With the advent of newer diagnostic equipment and the parameters that are now measurable, there is an opportunity to update our current classifications and definitions of keratoconus. The purpose of our paper is to propose and define terminology that reflects both our current knowledge and new data from diagnostic tests.

**Keywords:** Keratoconus, Classification, Tomography.

**How to cite this article:** Belin MW, Kim JT, Zloty P, Ambrosio R Jr. Simplified Nomenclature for describing Keratoconus. *Int J Keratoco Ectatic Corneal Dis* 2012;1(1):31-35.

**Source of support:** Nil

**Conflict of interest:** None declared

## DISCUSSION

Keratoconus, as a distinct clinical entity, was first described in the 1850s by British physician, John Nottingham. He described 'conical corneas' associated with weakening of the cornea, polyopia and suboptimal vision with spectacle correction.<sup>1</sup> In 1859, British surgeon William Bowman further contributed to the understanding of this disease, including a technique to detect the conical cornea with an ophthalmoscope. He also pioneered a surgical procedure involving the creation of a slit-like pupil as a form of treatment.<sup>2</sup> Though keratoconus has been described for several centuries, consensus on its definition and etiology continued to elude the ophthalmological world.

The original diagnosis was based solely on limited clinical findings. Typically, this disorder demonstrated bilateral, progressive, noninflammatory thinning and steepening of the central or paracentral cornea. Associated findings included but were not limited to high irregular astigmatism, a scissoring reflex on retinoscopy, an appearance of an iron ring at the base of the cone, and downward angulation of the lower lid on down gaze. These changes interfered with visual acuity and visual function, often prompting the subject to seek medical care. Before the advent of newer imaging modalities, diagnosis was confirmed with keratometry, which displayed irregular mires that did not superimpose. Advanced forms of keratoconus, as described above, are relatively easy to diagnosis. It is the earlier subtler forms of keratoconus that create diagnostic

challenges. The importance of detecting early disease has prompted many to try and classify or define ways of predicting the development of keratoconus before its clinical manifestations surface.

Amsler (1938) was the first to coin the term 'form fruste keratoconus'. He described a condition of slight ectasia and asymmetrical astigmatism, which was nonprogressive, and more often found in the fellow eye of a patient thought to have unilateral keratoconus or in family members of those with keratoconus. He used the handheld keratoscope (placido disks) to quantitatively define this entity, and suggested a cutoff of 4 degree or less of downward deflection of the horizontal axis as abnormal. A 4 to 8 degree deviation was qualified as mild keratoconus.<sup>3,4</sup> This, however, was not always a reproducible technique.

Mandell et al (1969) attempted to use corneal thickness measurements as a quantitative tool to detect early keratoconus. He recognized the spatial relationship of the anterior and posterior cornea as an important and early indicator of ectatic disease. He noticed that the difference between the central and peripheral corneal thickness was much greater in keratoconic corneas than in normals. A difference of more than 85 microns between the thinnest corneal point to a point 35 degree from that location, they thought, defined keratoconus.<sup>5</sup>

Rowsey et al (1981) used a topographic corneoscope to detect early stages of keratoconus. Abnormally compressed mires denoted areas of corneal steepening. Specifically for keratoconus, they found that the inferotemporal cornea steepened first and extended peripherally to involve the inferonasal quadrant, then the superotemporal and lastly, the superonasal quadrant.<sup>6</sup> This device provided greater corneal coverage than a flat handheld placido disk, but provided little information on the central cornea.

Genetics may also aid in the classification of and/or the predictability of developing keratoconus. Hammerstein performed a large prospective study and concluded that the risk of a keratoconic blood relative developing keratoconus was about 8%, with 20% penetrance, presuming autosomal dominance.<sup>7</sup> Hallerman et al did a retrospective review and found 7% of patients with keratoconus had at least one similarly affected blood relative.<sup>8</sup> More recent studies, utilizing corneal topography, have shown up to 50% of keratoconus patients with at least one blood with 'suspicious' topographic patterns.<sup>9</sup>

Other modalities, such as confocal microscopy to demonstrate changes in the number of corneal keratocytes

in keratoconus patients,<sup>10</sup> biochemical analysis to measure levels of enzyme activity<sup>11</sup> and the measurement of oxidative damage<sup>12</sup> have also been explored as ways to classify and determine predictability of developing keratoconus. These techniques still require much refinement and as of yet, do not offer clinical applicability.

Though there are aspects that require clarification, there has been a definite improvement in corneal imaging modalities that are used to detect early forms of keratoconus with higher sensitivity and specificity. It is now understood that keratometry and all placido-based methods, that only focus on the anterior corneal surface, will generate a substantial number of false negatives. While our diagnostic armamentarium has increased (computerized videokeratoscopes, rotating Scheimpflug optical cross-sectional analysis, confocal microscopy, optical coherence tomography, very high-frequency ultrasound, biomechanical analysis, etc.), our clinical terminology has stayed, for the most part, unchanged, forcing us to stretch some of the original meanings and force terms into uses outside of their original descriptions. With the dramatic increase in surgical procedures, particularly refractive surgery, that mandate the ability to identify early or subtle forms of ectatic disease, there has been a need to update and standardize our nomenclature. The purpose of our paper is to propose and define terminology that reflects both our current knowledge and new data from diagnostic tests. The proposed terminology cannot be static and will have to adapt as our knowledge advances and as this newer information (e.g. genetics, biochemistry, tomography and biomechanics) becomes more established in clinical practice.

We propose a simplified nomenclature that abandons confusing terms, such as ‘form fruste’ keratoconus. This classification uses minimal terminology and is based on diagnostic equipment commonly available. Keratoconus is defined as symptomatic or asymptomatic, based on whether

there is a reduction in best spectacle corrected visual acuity (BSCVA) or other clinically relevant measures of corneal visual performance, and progressive or nonprogressive based on either historical or diagnostic change. The changes (see below) may be related to loss in BSCVA, corneal wavefront, pachymetry (thinning) or further ectatic change on the anterior or posterior corneal surfaces. Suspect is reserved for patients with none of the above findings, but a strong family history or biomechanical measurements that fall outside the norm (this is still an area in development) or have suspicious corneal shape characteristics that are nonspecific for the condition.

This simplified nomenclature recognizes five clinical states (progressive symptomatic keratoconus, nonprogressive symptomatic keratoconus, progressive asymptomatic keratoconus, nonprogressive asymptomatic keratoconus and keratoconus suspect). The newly proposed nomenclature requires diagnostic measurements beyond placido anterior analysis and central corneal thickness (Table 1). The methods of obtaining data from the posterior surface, or corneal thickness distribution, e.g. are not specific to any single device or technique. Acceptance of this nomenclature would then allow for an updating of our commonly used grading criteria, as the currently used grading system is based on >20-year-old analysis (Amsler-Krumeich classification for keratoconus) and does not reflect much of the more recent diagnostic measurements.

Symptomatic keratoconus is defined by a loss of visual function secondary to changes on the anterior corneal surface. While changes on the posterior surface may lead to minor visual degradation, it is typically the anterior changes that are of sufficient quantity to have the patient seek evaluation/care. The anterior changes were traditionally and accurately called irregular astigmatism (where the principal meridians are nonorthogonal) or irregularly, irregular astigmatism (corneal distortion where the mires cannot be superimposed). These terms are still of practical

**Table 1:** Abnormal parameter distribution

	<i>Progressive symptomatic KNC</i>	<i>Nonprogressive symptomatic KCN</i>	<i>Progressive asymptomatic KCN</i>	<i>Nonprogressive asymptomatic KCN</i>	<i>KCN suspect (absence of secondary causes)</i>
Loss of BSCVA	+	+	-	-	-
Regular anterior astigmatism	-	-	+	+	+
Irregular anterior astigmatism	+	+	-	-	-
Kmax	+/-	+/-	+/-	+/-	+/-
Anterior curvature/skew deviation	+	+	-	-	-
Central corneal thickness	+/-	+/-	+/-	+/-	+/-
Anterior surface	+	+	-	-	-
Posterior surface	+	+	+	+	-
Thickness distribution	+	+	+	+	-
Family history	+/-	+/-	+/-	+/-	+/-
Biomechanics	+/-	+/-	+/-	+/-	+/-
Genetics	?	?	?	?	?
Change overtime	+	-	+	-	?

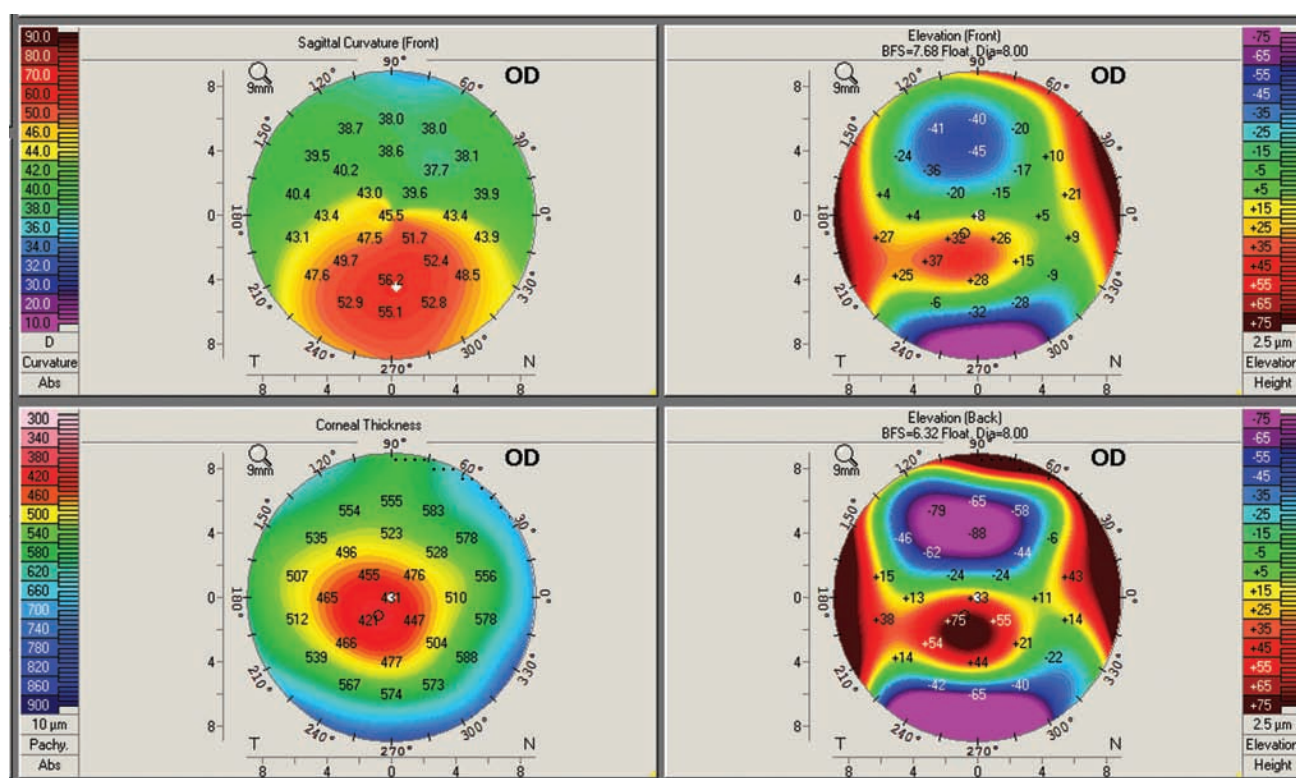
value and obviate the anterior curvature pattern classifications, which are fraught with false positives. Regardless of the curvature pattern, it is the nonorthogonal astigmatism that results in the majority of visual degradation. Additionally, these surface abnormalities are concomitant with other aberrations of the cornea. In the authors' experience, we have yet to see a case of true keratoconus with anterior changes that did not also have either changes on the posterior surface or abnormalities in corneal thickness progression (Fig. 1).

Asymptomatic keratoconus exhibits ectatic changes on the posterior corneal surface and/or changes in corneal thickness progression with regular anterior astigmatism (Fig. 2). While the anterior corneal surface may be steep (Kmax), it is the presence of regular anterior astigmatism that defines this condition. Minor degrees of visual loss (e.g. contrast sensitivity, high-order aberrations) may be present, but since the posterior corneal surface contributes minimally to the overall optical performance of the eye, these losses are typically not of sufficient quality and quantity for a patient to seek care (Fig. 3).

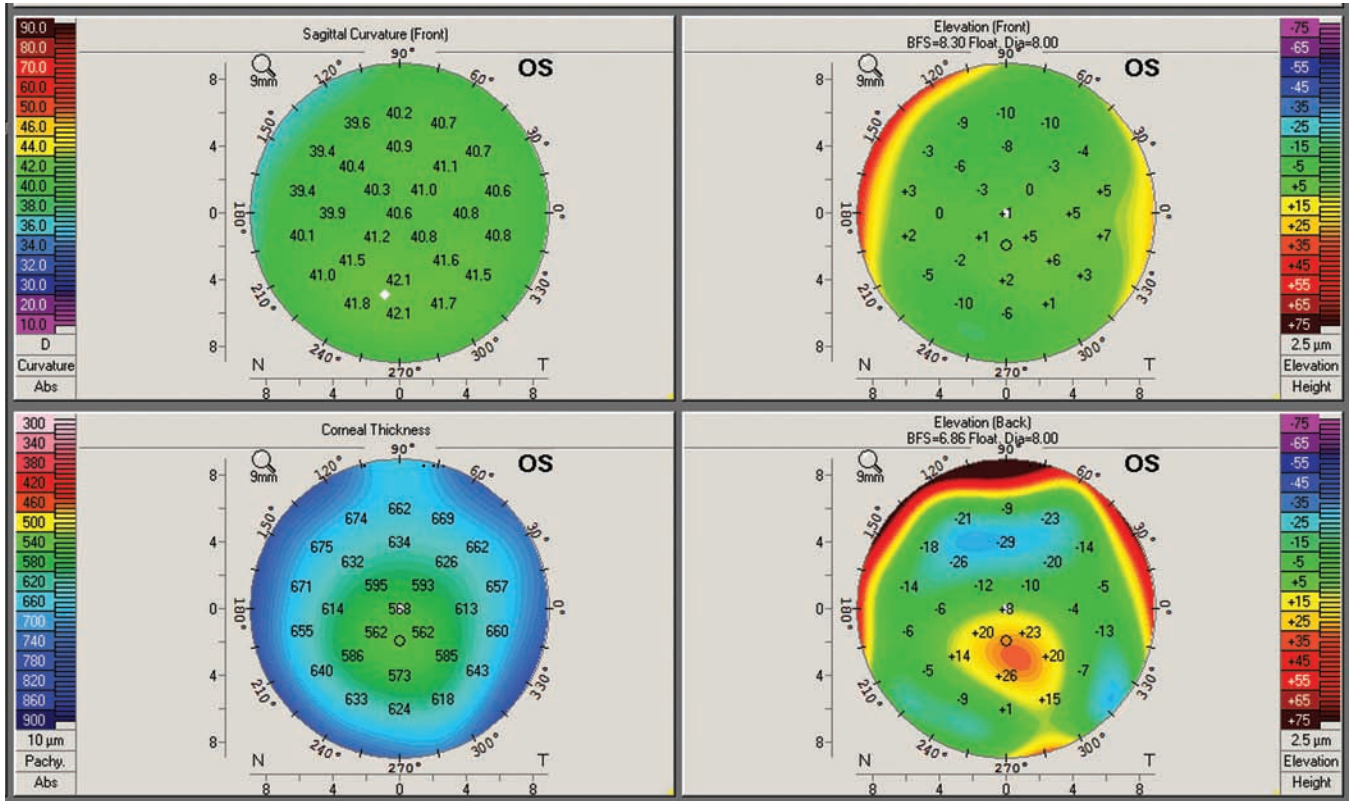
Progressive or nonprogressive disease is determined by an increasing loss of visual function, advancing ectatic change, or further corneal thinning. This is best documented by serial evaluations (e.g. tomography, topography with pachymetry) (Fig. 4). It is the patient's visual function and

degradation that is most important clinically, but visual function can remain stable in spite of progressing disease. The rate of keratoconus progression is quite individualized but does tend to decrease as the patient enters later life, typically the fourth or fifth decade. Progressive disease tends to become nonprogressive at this point.

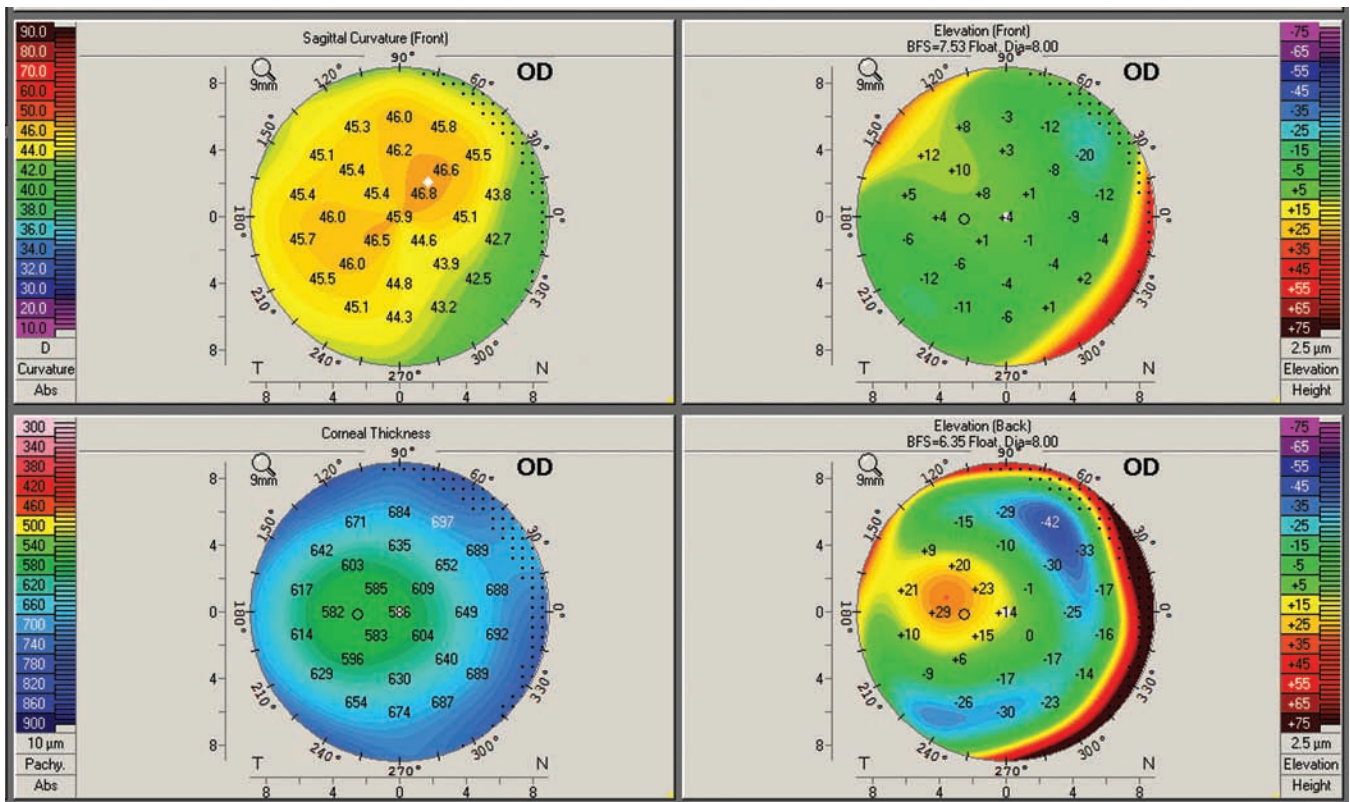
Keratoconus suspects may be identified by a number of different parameters. There is probably no greater controversy in our field other than what truly constitutes a keratoconus suspect. In the past, this group contained patients who have steep corneas, asymmetric topographic patterns, contact lens induced corneal warpage, high-order aberrations and thin corneas. Many of these parameters, in themselves, have little prognostic value or occur with sufficient frequency in normal individuals (e.g. asymmetric bowtie topographic pattern) to not justify their use as sole criteria. This group may eventually include patients with biomechanical abnormalities that place them at increased risk for keratoconus, but who do not yet demonstrate disease. This nomenclature seeks to define a keratoconus suspect as those patients who do not demonstrate overt disease, but have either a strong family history of ectatic disease or exhibit one or more known associated parameters (i.e. corneal thickness, anterior and posterior elevation, biomechanical change) that are significantly outside the normal range but do not meet the criteria of clinical disease.



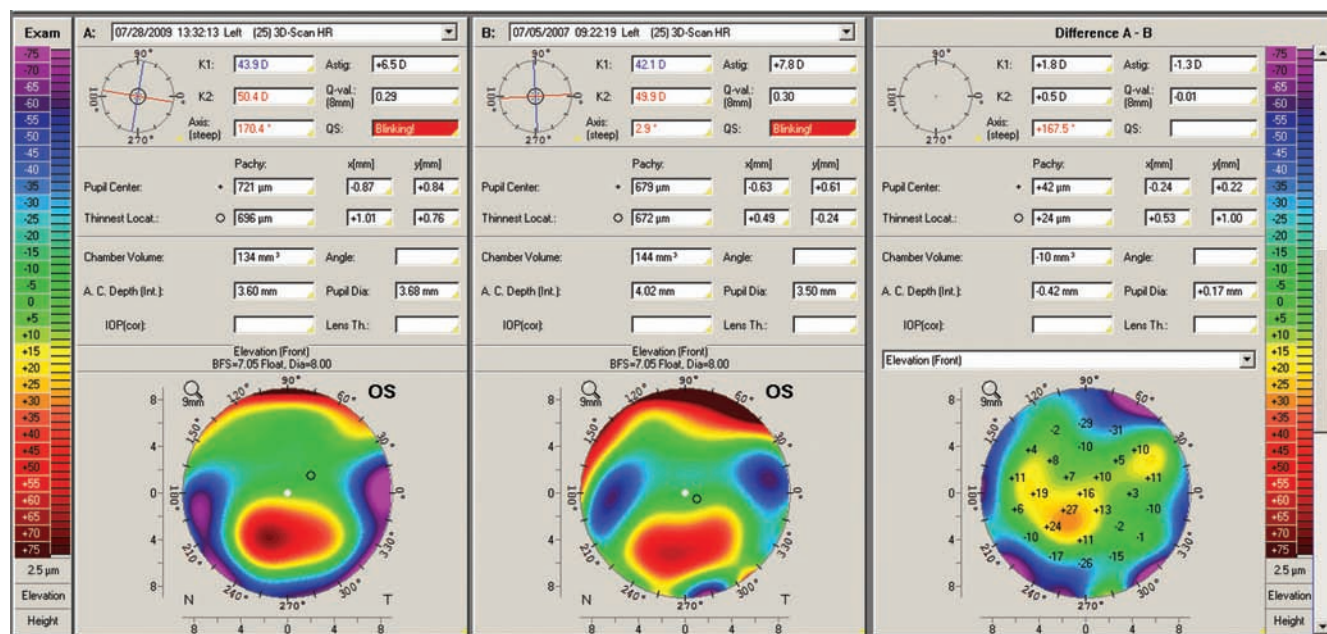
**Fig. 1:** Four maps composite display (anterior curvature, anterior and posterior elevation and corneal thickness) showing changes seen with symptomatic keratoconus. Both anterior curvature and elevation show prominent changes responsible for significant loss of BSCVA. The posterior elevation shows a prominent ectatic region (positive island of elevation) and the corneal thickness map reveals an abnormally thin cornea with the thinnest point displaced toward the ectatic region (Pentacam, Oculus GmbH)



**Fig. 2:** Four maps composite display revealing a normal anterior surface but a prominent posterior ectasia. The cornea has a normal central thickness, but the thinnest point is displaced toward the posterior ectasia. Because the anterior surface is normal, visual function is not significantly degraded (Pentacam, Oculus GmbH)



**Fig. 3:** Four maps composite display showing anterior regular astigmatism with a moderately steep cornea. Because the astigmatism is fairly regular, the patient retains good visual function in spite of the prominent posterior ectasia and thinnest point displacement (Pentacam, Oculus GmbH)



**Fig. 4:** Two maps comparison showing the change in anterior elevation over a 2-year period. The difference map (third map) shows over a 27 micron increase in elevation of the same best fit sphere demonstrating progression of disease (Pentacam, Oculus GmbH)

## CONCLUSION

Keratoconus can present a diagnostic challenge, particularly in its subclinical forms. Most of the earlier methods of classification relied heavily on older imaging modalities that focused on the anterior corneal surface. In light of newer diagnostic equipment and parameters that are now measured, classification criteria and organization should be carefully revised. We propose a simplified nomenclature that recognizes five clinical states (progressive symptomatic keratoconus, nonprogressive symptomatic keratoconus, progressive asymptomatic keratoconus, nonprogressive asymptomatic keratoconus and keratoconus suspect). These new classifications will serve to help clarify different states of keratoconus as well as provide clinicians with a better handle on the disease's prognosis and be equipped to impart appropriate patient education.

## REFERENCES

1. Nottingham J. Practical observations on conical cornea, and on the short sight, and other defects of vision connected with it. London: John Churchill 1854.
2. Bowman W. On conical cornea and its treatment by operation. In: Hulke JW (Ed). The collected papers of Sir William Bowman: Volume II miscellaneous, surgical and ophthalmological papers. London: Harrison and Sons 1892, 271-81.
3. Amsler M. Le keratocone fruste au javal. *Ophthalmologica* 1938;96:77-83.
4. Amsler M. Keratocone classique et keratocone fruste, arguments unitaires. *Ophthalmologica* 1946;111:96-101.
5. Mandell RB, Polse KA. Keratoconus: Spatial variation of corneal thickness as a diagnostic test. *Arch Ophthalmol* 1969;82:182-88.
6. Rowsey JJ, Reynolds AE, Brown R. Corneal topography. *Corneascope*. *Arch Ophthalmol* 1981;99:1093-1100.

7. Hammerstein W. Zur genetic des keratoconus. *Albrecht von Graefes Arch Klin Exp Ophthalmol* 1974;190:293-308.
8. Hallermann W, Wilson EJ. Genetische betrachtungen uber den keratokonus. *Klin Monatsbl Augenheilkd* 1977;170:906-08.
9. Goñzalez V, McDonnell PJ. Computer-assisted corneal topography in parents of patients with keratoconus. *Arch Ophthalmol* 1992;110:1413-14.
10. Ku JY, Niederer RL, Patel DV, Sherwin T, McGhee CN. Laser scanning in vivo confocal analysis of keratocyte density in keratoconus. *Ophthalmology* 2008;115:845-50.
11. Kao WW, Vergnes JP, Ebert J, Sundar-Raj CV, Brown SI. Increased collagenase and gelatinase activities in keratoconus. *Biochemical and Biophysical Research Communications*. 1982;107:929-36.
12. Behndig A, Karlsson K, Johansson BO, Brännström T, Marklund SL. Superoxide dismutase isoenzymes in the human eye. *Invest Ophthalmol Vis Sci* 1998;39:471-75.

## ABOUT THE AUTHORS

### Michael W Belin (Corresponding Author)

Professor, Department of Ophthalmology and Vision Science University of Arizona, Arizona, United States, e-mail: mwbelin@aol.com

### Joan T Kim

Resident, Department of Ophthalmology and Vision Science University of Arizona, Arizona, United States

### Peter Zloty

Attending Surgeon, Department of Ophthalmology, University of South Alabama, Alabama, United States

### Renato Ambrosio Jr

Director, Department of Ophthalmology, Instituto de Olhos Renato Ambrosio, Brazil